

Review

## A review of equine dental disorders

P.M. Dixon \*, I. Dacre

*Department of Veterinary Clinical Studies, Easter Bush Veterinary Centre, Easter Bush, Midlothian, Scotland, EH25 9RG, UK*

### Abstract

Equine dentistry is a very important but until recently rather neglected area of equine practice, with many horses suffering from undiagnosed, painful dental disorders. A thorough clinical examination using a full mouth speculum is a pre-requisite to performing any equine dental procedure. Common incisor disorders include: prolonged retention of deciduous incisors, supernumerary incisors and overjet – the latter usually accompanied by cheek teeth (CT) overgrowths. Overjet can be surgically corrected, but perhaps should not be in breeding animals. In younger horses, traumatically fractured incisors with pulpar exposure may survive by laying down tertiary dentine. Loss or maleruption of incisors can cause uneven occlusal wear that can affect mastication. Idiopathic fractures and apical infection of incisors are rare. The main disorder of canine teeth is the development of calculus of the lower canines, and occasionally, developmental displacements and traumatic fractures. The main indications for extraction of “wolf teeth” (Triadan 05s) are the presence of displaced or enlarged wolf teeth, or their presence in the mandible.

Developmental abnormalities of the CT include; rostral positioning of the upper CT rows in relation to the lower CT rows – with resultant development of focal overgrowths on the upper 06s and the lower 11s. Displaced CT develop overgrowths on unopposed aspects of the teeth and also develop periodontal disease in the inevitable abnormal spaces (diastemata) that are present between displaced and normal teeth. Diastemata of the CT due to excessive developmental spacing between the CT or to inadequate compression of the CT rows is a common but under diagnosed problem in many horses and causes very painful periodontal disease and quidding. Supernumerary CT mainly occur at the caudal aspect of the CT rows and periodontal disease commonly occurs around these teeth. Eruption disorders of CT include prolonged retention of remnants of deciduous CT (“caps”) and vertical impaction of erupting CT that may lead to large eruption cysts and possibly then to apical infections. Disorders of wear, especially enamel overgrowths (“enamel points”), are the main equine dental disorder and are believed to be largely due to the dietary alterations associated with domestication. If untreated, such disorders will eventually lead to more severe CT disorders such as shearmouth and also to widespread periodontal disease. More focal dental overgrowths will develop opposite any CT not in full opposition to their counterpart, e.g., following maleruption of or loss of a CT.

Because of the great length of reserve crown in young (hypsoodont) CT, apical infections usually cause infection of the supporting bones and depending on the CT involved, cause facial swellings and fistulae and possibly sinusitis. Diagnosis of apical infection requires radiography, and possibly scintigraphy and other advanced imaging techniques in some early cases. When possible, oral extraction of affected CT is advocated, because it reduces the costs and risks of general anaesthesia and has much less post-extraction sequelae than CT repulsion or buccotomy.

© 2004 Elsevier Ltd. All rights reserved.

*Keywords:* Horse; Equine dentistry; Equine dental anatomy; Incisor disorders; Developmental cheek teeth disorders; Acquired cheek teeth disorders; Apical infections; Dental tumours; Equine dental therapy

### 1. Introduction

Dental disease is the main oral disorder of horses and is of major importance in equine veterinary practice,

with up to 10% of practice time involving dental-related work (BEVA, 1965). Dental problems are the third most common medical problem in large animal practice in the USA (Traub-Dargatz et al., 1991). In addition, many postmortem studies have shown high levels of clinically significant, non-diagnosed dental disorders in horses (Wafa, 1988; Kirkland et al., 1994; Brigham and Duncanson, 2000a).

\* Corresponding author.

E-mail address: [pdixon@staffmail.ed.ac.uk](mailto:pdixon@staffmail.ed.ac.uk) (P.M. Dixon).

## 2. Clinical anatomy

The Modified Triadan system for equine dental nomenclature (Fig. 1) is used in this paper (Floyd, 1991).

Equine teeth have evolved to be hypsodont (long crowned) to cope with the high level of attrition associated with the prolonged (i.e., up to 18 h/day) mastication of their tough, silicate-containing, fibrous diet (Bennett, 1992; Capper, 1992).

The Triadan 05s (first premolar or “wolf tooth”) are vestigial if present, and Triadan 06s–08s (second–fourth premolars) are similar to the Triadan 09s–11s (molars), i.e., they have become molarised and therefore all six can conveniently be termed cheek teeth (CT) (Sisson and Grossman, 1971). Due to prolonged eruption of these teeth, areas not in apposition will develop overgrowths because of lack of wear. The disparity (ca. 23%) in distance between the mandibular and maxillary CT rows (Taylor, 2001) which is termed anisognathia, and the medial direction and great force of the normal masticatory movements influence the angulation of their occlusal surface, which is normally 10–15° (Easley, 1996). The four rows of CT need to function as single units and so all six CT are normally in tight contact at their occlusal surface, in order to prevent impaction of food in the interdental (interproximal) spaces. This is achieved by the caudally angulated Triadan 06s (first CT) and the rostrally angulated Triadan 10s and 11s (5th and 6th CT) compressing the rows of CT together at the occlusal surface. Inadequate or excessive angulation of these teeth may cause the developmental dental disorders of diastema and vertical impaction, respectively (Dixon, 2002).

In young horses, the long reserve crowns and apices of the CT lie deeply embedded in the supporting mandibular and maxillary bones and the maxillary paranasal sinuses. Consequently, infections of these teeth can also lead to infections of these bones or to maxillary sinusitis (O'Connor, 1930; Lane, 1993; Tremaine and Dixon, 2001a). Because of the prolonged eruption and sub-

sequent wear of equine teeth, the occlusal surface will not only contain enamel, as is the case with brachydont (e.g., human) teeth, but also dentine and cementum (Sisson and Grossman, 1971). The differential wear between these three components (enamel being hardest) will lead to the development of protruding enamel ridges on the occlusal surface. The presence of two infolded enamel cups (infundibulae) in upper CT and one infundibulum in the incisors, and deep infolding of peripheral enamel in all CT increases the length of exposure of the protruding enamel folds. More complete reviews of equine dental anatomy are presented by Easley (1996) and Dixon (1999, 2002).

The aging of horses has traditionally, but sometimes erroneously, been performed by incisor appearance. Following some critical studies on its value, as reviewed by Muylle (1999), most practitioners are much more cautious of the value of this technique to age horses, particularly mature horses.

## 3. Clinical signs of dental disease

The most common equine dental (and oral) disease is the development of sharp dental overgrowths, often termed ‘enamel points,’ although these overgrowths will also include cement(um) and dentine if they become large. These overgrowths develop on the lateral (buccal) edges of the maxillary and the medial (lingual) edges of the mandibular CT and may cause lacerations of the cheeks and tongue during chewing (Becker, 1962). Likewise, soft tissue injuries from more focal dental overgrowths (colloquially and interchangeably termed “hooks”, “beaks”, “steps” or “ramps”) from displaced teeth or from pain due to deep secondary periodontal disease (usually due to abnormal spaces between or beside the teeth – as discussed later) may result in small boluses of partially masticated food falling from the mouth during chewing, a condition termed ‘quidding’ (Scrutchfield and Schumacher, 1993; Easley, 1999a).

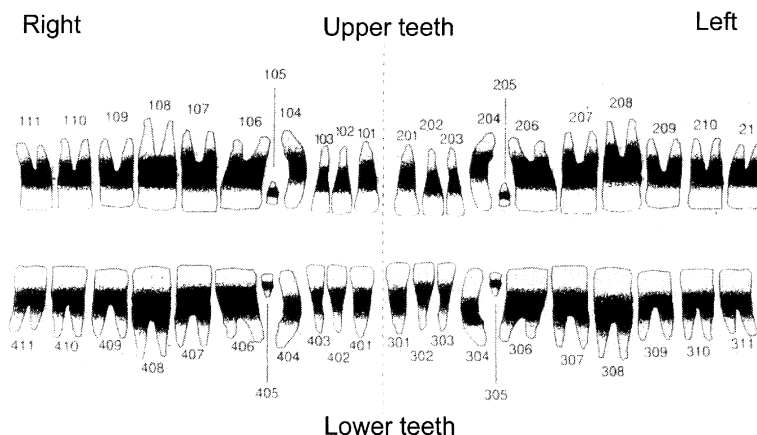


Fig. 1. The Triadan system of equine dental nomenclature.

Quidding often occurs during the early oral phase of swallowing and thus could be termed an oral dysphagia. Boluses of such “quidded” food may be visible on the ground outside the animal’s box or beneath the forage rack.

Horses with dental overgrowths or other causes of dental pain may not fully clear their mouth of food and thus semi-permanent ‘hamster-like’ cheek swellings may occur in severely affected horses, due to the accumulation of fibrous food packed between the lateral aspects of the CT and the cheeks. Horses possibly accumulate this food deliberately to protect their cheeks from sharp overgrowths on the buccal aspects of the upper CT.

The presence of oral pain dissuades the horse from making normal, full distance, very forceful masticatory grinding movements and due to this restriction of jaw movements, generalised dental overgrowths may then develop (Becker, 1962). Later, these large dental overgrowths will also mechanically prevent the normal full range of lateral movement of the mandible. Due to oral pain, some horses may also chew very slowly and whilst doing so, make soft ‘slurping’ sounds rather than the normal vigorous ‘crunching’ masticatory sounds.

Horses with unilateral oral pain may only use one side of their mouth for chewing, rather than using alternate sides, or they may hold their head in an abnormal position during eating. Affected horses often readily eat grass or soft mashes but may be reluctant to eat hay or silage (haylage) and may then quid when doing so. Therefore in many cases, the clinical signs of dental-related pain only become apparent when horses are brought indoors and fed hay in winter. Long strands of forage and undigested whole grain particles may be present in the faeces, indicating that these foodstuffs were insufficiently masticated for the large intestinal flora to digest.

Halitosis may be present if widespread periodontal disease, or less commonly, when advanced dental caries is present (Dixon et al., 2000a,b). In extreme cases, decreased food intake and/or inefficient food digestion and utilisation may eventually occur, leading to weight loss. However, most horses with dental-related pain will just spend longer eating, including re-eating “quidded” food off the ground. Therefore the absence of weight loss does not indicate the absence of dental disease. In fact, weight loss is an unusual finding even in horses with many types of serious dental disease, including apical (periapical) infections (the term ‘tooth root’ infection is inaccurate, as many of these infections occur before any true root develops) (Dixon et al., 2000b).

Painful, dental-related lesions may also cause bit (bitting) problems, including abnormal head carriage, resistance to the bit and headshaking during work (Scrutchfield, 1999a). This is often because enamel overgrowths, especially of the protruding vertical ridges (sometimes termed cingulae) on the buccal aspect of the

upper 06s and 07s traumatise the buccal aspects of the cheeks due to overlying pressure from nosebands, bits, headpieces or cavesson. Less commonly, the tongue can be compressed by the overlying bit and forced against sharp overgrowths on the rostral or medial aspects of the lower CT (06s), and this may also cause pain. Other signs of dental disease (especially of apical infections) include facial swellings, especially of the mandible or the rostral maxilla. The presence of draining sinus tracts from such swellings provides further evidence of likely CT infection (most likely of apical infection).

The presence of a chronic unilateral nasal discharge (purulent or mucopurulent and possibly malodorous) may be caused by a secondary dental sinusitis (i.e., rostral or caudal maxillary sinusitis caused by infection of the upper 08s–11s) (O’Connor, 1930). Less commonly, periapical infection of the upper 06s, 07s or occasionally of the 08s will discharge medially into the nasal cavity, also causing a chronic, unilateral, (muco-) purulent nasal discharge (Dixon et al., 2000b). More commonly, infection of the rostral maxillary CT (06s and 07s) will cause a facial swelling and sinus tract formation lateral to the infected apex (dorso-rostral to the rostral aspect of the facial crest). These signs of dental infection are more likely to occur in younger horses that have longer reserve crowns (Dixon et al., 2000b).

In older horses, apical infections usually drain via the periodontal space of the shorter alveolus into the mouth (with resultant halitosis and possibly periodontal pain and quidding), and therefore significant infection of the supporting bones of the face is usually absent. Bilateral swellings of the ventral aspect of the mandible are usually due to eruption “cysts” of the adjacent developing apex in three to four-year-old horses (Dixon et al., 2000a), but *unilateral* swellings are most commonly caused by apical infections (Baker, 1999; Dixon et al., 2000b). However, identical unilateral lesions can also be caused by external trauma (often due to kicks) (Greet, 1999) and less commonly by bone or dental tumours (Pirie and Dixon, 1993).

A chronic painful or mechanical dental lesion that causes long-term mastication on only one side of the oral cavity will eventually induce an abnormal wear pattern on the incisors, i.e., they develop a diagonal occlusal surface (“slopemouth”, “slantmouth”) as well as causing abnormal CT wear, as discussed later (Scrutchfield and Schumacher, 1993; Easley, 1999a; Dixon et al., 1999a). The presence of abnormally angled or positioned incisor teeth may also indicate that a displaced fracture of the jaw has occurred.

#### 4. Examination of equine teeth

Palpation through the cheeks may reveal food pocketing or detect major dental irregularities (such as a

missing tooth or a large overgrowth) of the rostral three to four upper CT. Even if no such abnormality is palpated, the presence of pain (i.e., the horse pulling away or flinching) during this procedure may indicate the presence of sharp overgrowths on the buccal aspect of the upper CT (Scrutchfield and Schumacher, 1993; Easley, 1999a).

Observation of horses during mastication may reveal visibly restricted mandibular movements that may even be confined to one side of the mouth and also, the absence of normal vigorous grinding sounds. By fixing the upper jaw with one hand, the degree of lateral mandibular movement and the animal's response to this manipulation can be manually and visually assessed (Ralston et al., 2001; Rucker, 2002). This manoeuvre can be difficult in un-cooperative horses without sedation. On moving the mandible sideways by between 0.5 and 2.5 cm, the sloped occlusal surfaces of the lower CT should come into contact with the sloped occlusal surface of the upper CT, and on further lateral movement of the mandible, this occlusal contact between the angled CT should push the incisors apart (Rucker, 2002). After initial cheek teeth contact, further lateral movement of the mandible by one cm should cause incisor separation of between 2 and 6 mm in normal horses (Rucker, 2004). By judging the distance before the incisors separate, and their degree of separation on further mandibular movement, the angulation of the occlusal surface of the CT can be evaluated (Rucker, 2002, 2004).

It is impossible (and dangerous) to properly examine a horse's mouth without the use of a full mouth gag (speculum) (Scrutchfield, 1999a). For reasons of safety, a minority of horses (ca. 3–8%), dependent on temperament and prior experience of oral examination, will need to be sedated for dental examination (Brigham and Duncanson, 2000b; Ramzan, 2002). Repeat oral examinations can usually be performed without sedation once a horse realises that use of the gag is not painful. A nose twitch may be required to provide further restraint in some horses, however with gentle encouragement, most horses can be safely examined using a gag at the initial attempt, without any additional restraint. Once the speculum is fitted, pushing the thumb off the hard palate will often cause the horse to open its mouth further, allowing additional opening of the gag. Food retained in the oral cavity (which further retards visual examination) should be removed by flushing the mouth with large syringes of water (or very dilute chlorhexidine), or by manual removal of large food accumulations – followed by such flushing.

Due to a combination of factors, including the limited angle of opening of the equine mouth (it being a herbivore), the rostral positioning of the lip commissures and the great length of their oral cavity, it is difficult to fully visually examine the CT – particularly the caudal mandibular CT. The use of a headlight (a penlight torch

is much less satisfactory), dental mirror and a flat rasp or a specialised metal examination basket (to displace the tongue) can greatly facilitate visual examination of the equine mouth (Scrutchfield and Schumacher, 1993; Easley, 1999a). The use of a long dental mirror or intra-oral endoscopy can reveal subtle lesions (pulpar exposure, localised periodontal food pocketing) of the caudal oral cavity that would otherwise be impossible to visualise.

Major problems, especially of the caudal lower CT and the adjacent periodontal membranes and gums, can also be missed unless all the teeth and adjacent soft tissues (gingiva) are carefully palpated. It is also useful to smell one's hand after oral examination for the presence of malodour, which usually indicates anaerobic infections, most commonly caused by secondary periodontal disease (due to food pocketing).

As noted, CT apical abscessation is a major dental disorder, especially in younger horses, and is usually accompanied by infection of the supporting bones. In many such cases, no changes are visible on oral examination of the clinical (erupted) crown, even if these apical infections are very long-standing, except when the apical infection was caused by advanced pre-existing infundibular cemental caries (upper CT only). However, very careful examination of areas of secondary dentine, including use of a mirror and a fine dental pick, may reveal evidence of pulpar exposure, i.e., pitting or deeper defects of secondary dentine on occlusal surface (Dacre, 2004). Radiography and possibly other imaging of dental apices and reserve crowns are therefore essential in the investigation of such disorders (Gibbs, 1999).

## 5. Disorders of the incisor teeth

Compared to the CT, significant disorders of the equine incisors are relatively uncommon (Dixon et al., 1999a). However, as owners can easily visualise these teeth (without a gag), even minor incisor problems are apparent, in great contrast to CT disorders.

### 5.1. *Overjet* (“parrot mouth”)

Many horses have some degree of overjet (‘parrot mouth’ ‘overshot jaw’). This is commonly termed (mandibular) brachygnathism, but there is some evidence that it is actually due to overgrowth of the upper jaw (Miles and Grigson, 1990). In some cases, the overjet is so excessive that the unopposed upper incisors will grow down below the level of the lower incisor occlusal surface (overbite) (Fig. 2). The upper incisors may now mechanically trap the lower incisors and restrict mandibular growth and so further exaggerate the disparity between the length of the upper and lower jaws. This disorder is aesthetically undesirable especially in

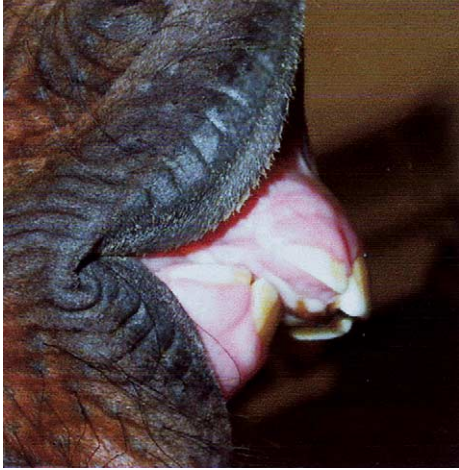

Fig. 2. This foal has marked overjet (ca. 2 cm), but as yet, minimal overbite of its upper incisors.

show horses, however, unless contact between opposing incisors is totally absent, it rarely causes difficulty in prehension (Easley, 1999b). As the more rostral 01s (central incisors) have the least occlusal contact and overgrow most, more severely affected horses develop a convex appearance of their upper incisor occlusal surface (termed a ‘smile’), which should be reduced (in stages if the incisor overgrowths are large in order to prevent pulpar exposure) (Dixon et al., 1999a). In contrast to CT rasping (floating), many horses greatly resent incisor teeth floating and require sedation for this procedure.

The main clinical significance of incisor overjet is that it is usually associated with CT disorders, with the upper CT row being rostrally positioned in relation to its lower counterpart. This leads to focal overgrowths on the rostral aspects of the upper 06s and the caudal aspects of the lower 11s that can cause major biting and masticatory problems. In less severe cases, a slight overbite

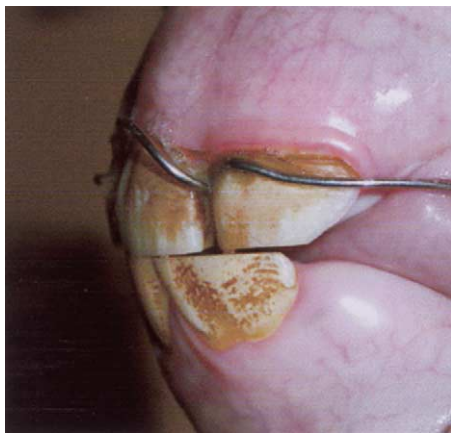

Fig. 3. This foal has successfully had a 15-mm overjet corrected using an orthodontic brace placed between its cheek teeth and incisors.

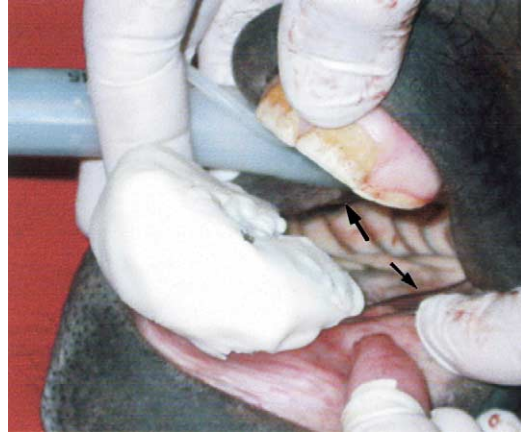

Fig. 4. A foal with marked overjet is having an orthodontic wire brace (arrowheads) fitted. Because of the extent of the overjet, a “bite plate” (composed of a perforated aluminium plate and acrylic) is also being fitted to prevent the prosthesis from bending the premaxilla ventrally, causing overbite.

can be associated with “exaggerated” transverse ridges or sloping overgrowths of the caudal CT. After reduction of the slight overbite, correction of the latter CT overgrowths may prevent the overbite from recurring.

Overjet in foals can be treated by orthodontic therapy, i.e., wiring the upper incisors to the upper CT to restrict growth of the premaxilla and maxilla (Easley, 1999b) (Fig. 3). If an overjet is large and especially if overbite is also present at this stage, a “bite plate” also needs to be fitted to affected foals (Fig. 4) to prevent the prosthesis from causing caudal angulation of the premaxilla. Due to the possible hereditary nature of this disorder, the ethics of these procedures are debatable in animals that might be used for breeding. Additionally, some breed associations do not allow surgical correction of overjet in registered horses.

### 5.2. Underjet

Underjet (prognathism, “sow mouth”, “undershot jaw”) is rare in horses and is usually of little clinical significance, unless there is total lack of occlusion between teeth. Such cases may develop focal CT overgrowths on the *upper* 11s and the *lower* 06s. Due to preferential overgrowth of the central lower incisors, such cases develop a concave occlusal surface of their upper incisor occlusal surface (termed a ‘frown’). As with overbite, major incisor overgrowths (and concurrent CT focal overgrowths) should be rasped level twice yearly.

### 5.3. Retained deciduous incisors

Deciduous incisors are occasionally retained beyond their normal shedding time, usually rostral to the erupting permanent incisors – i.e., on their labial aspect.

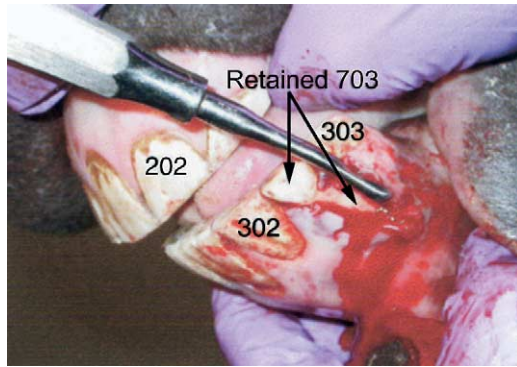


Fig. 5. This 303 has erupted caudal (lingual) to its deciduous counterpart and has displaced 703 slightly rostrally. There has been no resorption of the apex of 703 from the erupting 303 and thus a great length of the retained 703 still remains. The rostral aspect of the alveolus of 703 has been removed and the tooth is being loosened using a dental elevator.

These retained teeth can cause the permanent incisors to be displaced lingually (i.e., caudally) and if retained for long enough, e.g., >12 months, may cause permanent changes to the incisor occlusal surface (Scrutchfield and Schumacher, 1993). Retained deciduous incisors can be extracted using dental elevators, possibly using sedation and local anaesthesia (Fig. 5). Deciduous incisors that are retained on the lingual aspect of the permanent teeth are more difficult to extract (Alexander et al., 2001).

#### 5.4. Supernumerary permanent incisors

Supernumerary permanent incisors (i.e., incisors that are additional to the normal six incisors on each arcade) are usually morphologically identical to the normal incisors and so are termed supplemental incisors (Miles

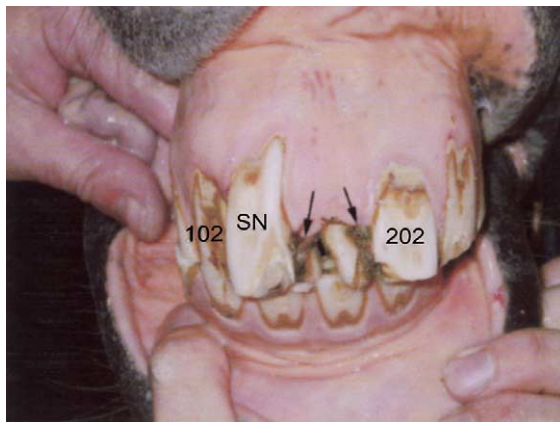

Fig. 6. A supernumerary incisor (SN) in the first dental quadrant (upper right) of this horse has caused overcrowding and lingual displacement of 101 and 201, with secondary diastemata and periodontal food pocketing (arrowheads). Extraction of this supernumerary incisor would not be difficult because it is rostrally displaced. Its removal might allow normal eruption of 101 and 201.

and Grigson, 1990). In young horses, these teeth may have very long (<7.0 cm in length) reserve crowns and roots, that are often intimately related to the reserve crowns and roots of the normal permanent incisors. Unless the reserve crown is rostrally displaced and thus protruding beneath the gingiva (Fig. 6), extraction of these supernumerary teeth is very difficult and also risks damaging the adjacent normal incisors (Dixon et al., 1999a). Unless grossly displaced, supernumerary incisors usually cause little clinical problems and are best not extracted (except perhaps in show horses). Twice yearly rasping of unopposed areas of these incisors should be performed to prevent overgrowths developing.

#### 5.5. Incisor fractures

Incisors rarely develop idiopathic fractures compared to CT, despite their smaller size, less mechanical support from their adjacent teeth and the fact that they undergo greater shearing stresses, e.g., while tearing hay from hay nets (Dixon et al., 1999a). This resistance to fractures can be attributed to the interwoven type of enamel that incisors mainly consist of, i.e., Equine type 2 enamel (Kilic et al., 1997a). Minor occlusal fractures of the incisor teeth can occur due to stereotypic behaviour (“crib-biting”) but this behaviour more commonly causes abnormal wear (abrasion) on the labial aspects of the more rostral incisors (01s and 02s).

Head trauma (usually from kicks) can result in compound (open) fractures (i.e., fracture with exposure of the pulp cavities) of the incisors, which are the most exposed equine teeth and thus vulnerable to trauma (Hague and Honnas, 1998; Dixon et al., 1999a) (Figs. 7

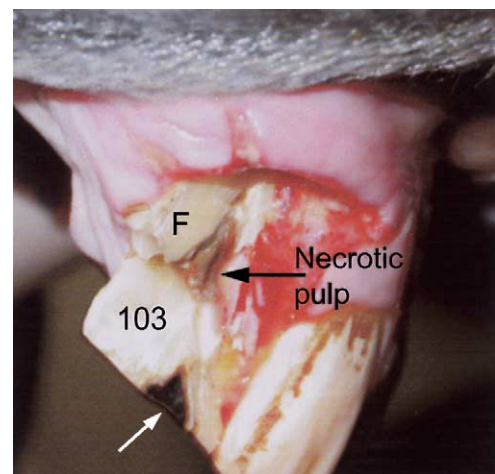


Fig. 7. This horse has suffered a traumatic compound (involving the pulp) fracture of an incisor (103) some four days earlier. Some dental fragments (F) remain loosely attached and an area of devitalised pulp is protruding from the main residual part of the tooth (103). The remnant of the infundibulum is also exposed (white arrow).

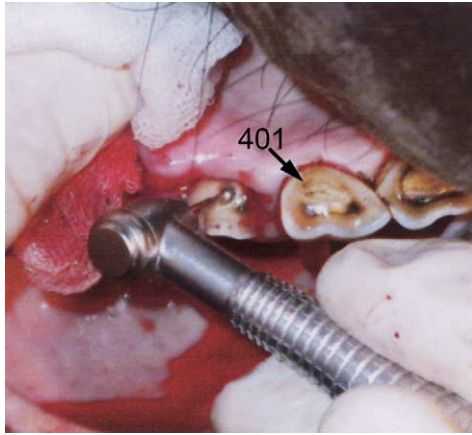


Fig. 8. This horse suffered a traumatic, compound fracture of 402 and 403 some days previously and is currently having the 403 pulp canal undercut to allow endodontic treatment of the still vital pulp.

and 8). The teeth of young horses contain very wide apical foraminae and also have very large and vascular pulps. These pulps can usually tolerate the inflammation that occurs (including by inevitable pulpar infection) following such fractures and still maintain their blood flow. Consequently, incisor fractures with pulpar exposure, especially in younger horses, does not necessarily lead to pulpar ischaemia and tooth loss, as usually occurs with pulpar exposure in brachydont dentition (Dixon et al., 1999a). In many horses (especially when young), the occlusal aspect of the exposed pulp will become sealed off by reparative (tertiary) dentine formation, with the tooth remaining vital and continuing to erupt normally. Antibiotic therapy, including penicillin and metronidazole, and anti-inflammatory therapy, are possibly of value in the acute stages of dental fracture. Endodontic (root canal) treatment (Fig. 8) can be performed on fractured incisors with exposed pulp, but the efficacy of this treatment in horses of various ages needs to be critically assessed. Following an incisor fracture, the opposing incisor(s) will overgrow into the site of the shortened or absent incisor(s) due to lack of attrition (Fig. 9), and these overgrowing incisors should be rasped twice yearly (Crabill and Schumacher, 1998; Scrutchfield, 1999a).

### 5.6. Incisor occlusal surface abnormalities

Abnormalities of the occlusal surfaces of the incisors may include local overgrowths ('steps') caused by the developmental absence of, or later loss of, partial fracture or maleruption of the opposing incisors (Scrutchfield, 1999a) (Fig. 9). Unless both upper and lower incisor occlusal surfaces are parallel, they will mechanically prevent the normal, medially directed masticatory action ("power stroke") of the CT and lead to secondary CT wear abnormalities. As noted, a diagonal ("slant-

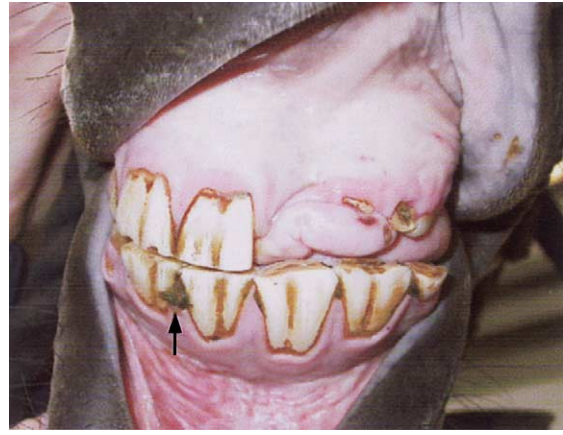


Fig. 9. This horse has left-sided premaxillary gingival deformation and absence of 201. Some small remnants of the clinical crown of 202 and a normally erupting 203 are visible. These upper incisor changes are most likely due to trauma. Secondary overgrowths have developed on 301 and 302, opposite the absent and shortened teeth, respectively. Reduction of the overgrown 301 and 302 are required to allow normal lateral masticatory action. Note also the diastema and food trapping between 401 and 402 (arrow).

mouth") incisor occlusal surface will develop in horses grinding in only one direction (Fig. 10) and secondary incisor occlusal abnormalities also occur with overjet and underjet. Only rarely will incisor abnormalities (even major) lead to difficulties in prehension. Indeed, even surgical removal of all of the upper or lower incisors (due to tumours) seldom leads to significant prehension difficulties, once horses learn to prehend with their mobile lips and tongue.

After recognition of incisor irregularities, the CT should then be carefully assessed and if present,

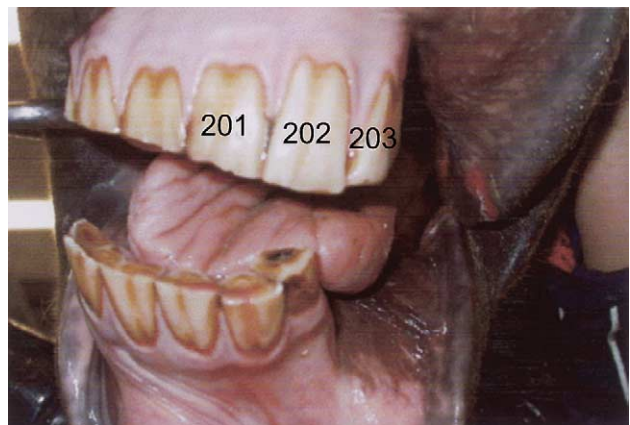

Fig. 10. This horse has a marked "slope mouth" ("slant mouth") following trauma of the left trigeminal nerve and thus paralysis of the left muscles of mastication, some four years earlier. Developmental medial displacements of both lower 03s are also present. Some iatrogenic lip trauma has occurred during mechanical reduction of large, left-sided cheek teeth overgrowths caused by the lack of occlusal wear on that side.

predisposing CT abnormalities should be treated. Following reductions of CT crown heights, incisor irregularities should then be reduced, using motorised instruments if these overgrowths are large (Scrutchfield, 1999a,b). Care must be taken to prevent possible pulpar exposure during such treatments; because unopposed teeth erupt at a faster than normal rate and additionally have minimal stimulation of odontoblast processes on their occlusal surface that normally promote the laying down of secondary dentine (Kempson et al., 2003). Incisor reductions should be performed in stages if major overgrowths are present, to promote secondary dentine deposition above the underlying pulp.

### 5.7. Generalised incisor overgrowths

Some operators (mainly lay equine dental technicians) believe that generalised incisor overgrowths commonly cause the CT to be held apart and prevent proper mastication and thus they remove large amounts of incisor crown to correct this “abnormality”. It is difficult to justify such procedures from a mechanical viewpoint (Dixon et al., 1999a) and indeed the widespread exposure of incisor pulps in some cases where this procedure is performed is further evidence of its incorrectness. However ca. 1% of older horses may have minimal or no CT separation when their mandible is moved laterally, due to minimal CT occlusal surface angulation (Rucker, 2004) and may benefit from incisor reduction of 1–3 mm. As noted, horses that have had major overgrowths of their CT removed may require some generalised incisor reductions (Scrutchfield, 1999a).

### 5.8. Incisor apical infections

For poorly understood reasons, equine incisors seldom develop apical infections as compared to CT. Incisor infections are usually manifested by a sinus tract in the gingiva, which exit level with the apex of the affected tooth. The infected tooth may also be slightly darker in colour and have localised gingival retraction. Unless loose, or associated with gross alveolar sepsis, affected incisors should be left in situ to prevent drifting of the adjacent incisors and overgrowth of opposing incisors. Endodontic therapy would be of value for such cases if their periodontal membrane remains generally healthy.

### 5.9. Incisor diastema(ata)

All incisors taper in towards their apices, however, rostro-medial (rostro-mesial) compression from the 03s usually keeps the occlusal aspect of the incisor arcade acting as a single unit, as the incisors wear with age. Small (ca. 1 mm) diastemata can develop on the occlusal surface in some older horses, with wider (e.g., >5 mm

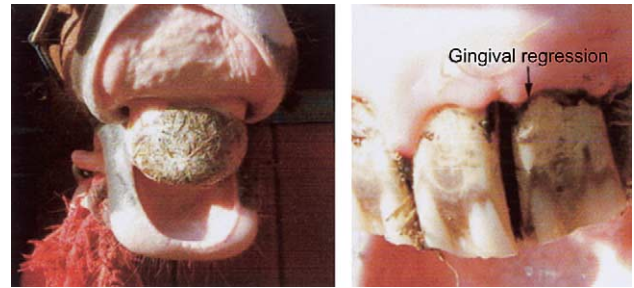

Fig. 11. Left: This horse has diastema of its upper incisors with entrapment of a large quantity of fibrous food between these teeth, which is now covering all the upper incisors. Right: Incisors with diastema showing gingivitis and gingival regression. Fig. courtesy of N. Zilac.

wide) spaces present more apically (“valve diastemata”). These smaller diastemata can tightly trap food and cause periodontitis and gingival retraction (Fig. 11). It is often very difficult (and dangerous) to manually remove food from the lingual (caudal) aspect of these incisor diastemata and some affected horses may have a permanent, 3–4 cm deep mat of fibrous food protruding rostral and caudal to their incisors. Treatment is simply by widening the diastemata on the occlusal surface to 3–4 mm wide, using a mechanical diamond-coated wheel or a hand-held hacksaw blade and then have the owners brush any further trapped food out using a toothbrush, daily initially. Wider diastemata that are commonly present in aged horses do not usually cause a clinical problem, as they tend not to trap food.

## 6. Disorders of the canine teeth (04s)

The canine teeth (04s, “tushes”) are usually only present in male horses, with vestigial 04s present in a small proportion of female horses. These teeth do not anatomically oppose each other, and this may be the reason why calculus, often extensive, accumulates on the more rostrally positioned lower canines. Unlike brachydont teeth, dental calculus is not a major predisposing factor to periodontal disease in horses, although extensive calculus formation at this site will cause gingivitis, local periodontal disease and may occasionally cause ulceration of the adjacent lips. This calculus can be readily removed with strong forceps and the above-noted periodontal disease will then usually regress, due to the ability of equine periodontal membranes to reform, even in adult horses.

Apical infections of the canine teeth rarely occur and trauma (with pulpar exposure) may pre-dispose to infection in some of these rare cases (Figs. 12 and 13). Affected teeth may need to be extracted. Occasionally, displaced or grossly enlarged canine teeth may interfere with the bit and such teeth should be reduced in size. Rarely, a displaced canine tooth will need to be



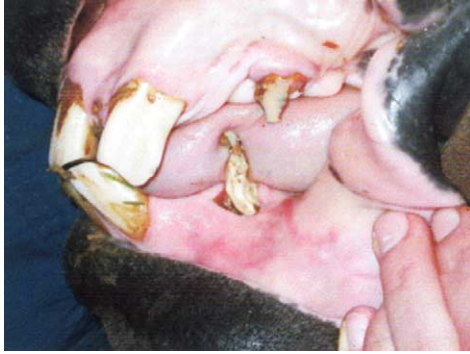

Fig. 12. This lower canine tooth (304) has advanced caries of the clinical crown with deep periodontal pocketing. The upper canine (204) is shortened and darkened. The right-sided canines were of normal appearance. Trauma may have predisposed to these canine teeth disorders.

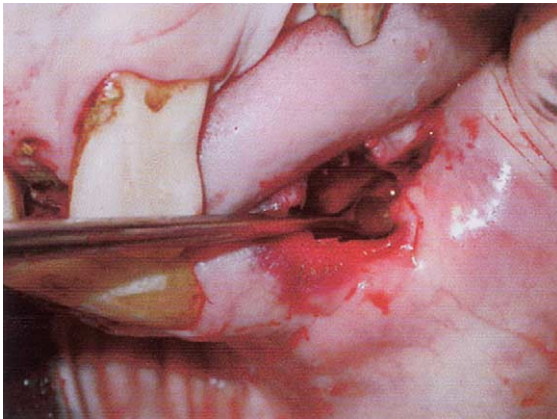


Fig. 13. The diseased canine tooth in Fig. 12 has been extracted using sedation and local (mental nerve) anaesthesia and the alveolus is now being curetted with a spoon curette.

extracted. Due to the great length (up to 7 cm long) and strong periodontal attachments of their reserve crown, and the fact that they erupt slower than other equine teeth, general anaesthesia may even be necessary for some canine teeth extractions.

Some veterinarians advise that the sharp aspects of the clinical crown, or even most of the clinical crown of the canine teeth should be ground down, especially in performance horses that are having regular (e.g., six monthly) prophylactic dental examinations. This is because these teeth can cause laceration of the operator's hands and arms during dental procedures; allegedly may interfere with the bit in some animals and may inflict damage to other horses during fighting. There is no agreement on this issue. Excessive reduction of these teeth can lead to pulpar exposure, which is painful and inhumane, and also may predispose to canine teeth apical infection, possibly many months or years later.

## 7. Disorders of the 1st premolar (“wolf teeth”, 05s)

Wolf teeth are small (usually 10–20 mm long) brachydont teeth with variable sized (5–30 long mm) roots. They erupt at between 6 and 12 months of age and may be lost when the adjacent temporary 06s are shed at ca. 30 months of age. Remnants of the first deciduous CT (506/606) may resemble “wolf teeth” (Fig. 14). The presence of “wolf teeth” is blamed for many behavioural problems in horses and for interfering with the bit, and therefore, these teeth are frequently extracted. Some use the argument that because these teeth never do any good and may on occasions cause a problem, they should always be removed. However, normal sized and positioned “wolf teeth” are sometimes found in older riding horses competing to a very high level that have no history of biting problems.

It is however, generally accepted that enlarged, rostrally, rostro-laterally or medially displaced 05s of the upper jaw or any mandibular 05s, may cause oral pain due to bit contact, or if the bit pulls the cheeks on to sharp “wolf tooth” protuberances (Fig. 15). Such “wolf teeth” can more rationally be extracted. Very rostrally displaced wolf teeth must be differentiated by radiography from canine teeth, which as noted, have long reserve crowns even in adults. Wolf teeth can be extracted using local anaesthesia and sedation, utilising a variety of specialised elevators or forceps (Scrutchfield, 1999a). Wolf tooth extraction is not necessarily an innocuous procedure as all or part of their crown can be hidden beneath soft tissue and they can also be large, with deeply embedded roots (Fig. 16). The greater palatine artery and the hard palate can be lacerated during this procedure, and soft tissue infections or tetanus may also occur following this surgery. Fractures of “wolf teeth” during extraction, with part of the tooth left remaining *above* the alveolus can lead to permanent, painful local

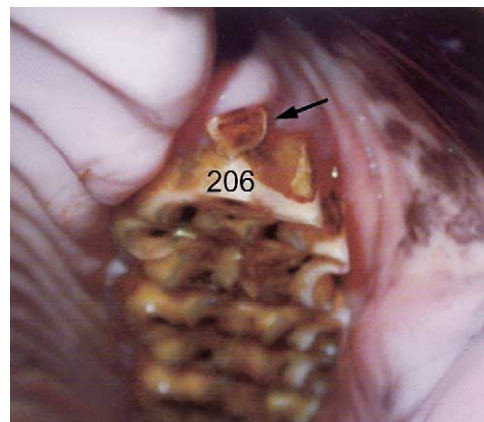


Fig. 14. A small, flat mobile remnant of a first deciduous cheek tooth (606) (arrowhead) remains in front of 206 (which has a small rostral overgrowth) and resembles a “wolf tooth”. Alleged supernumerary “wolf teeth” can be due to such deciduous CT remnants.

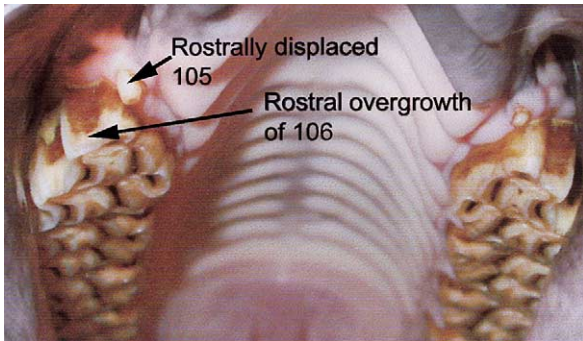


Fig. 15. This horse has a large, rostrally displaced 105 (“wolf tooth”). A smaller 205 is also present. Focal rostral overgrowths are also present on 106 and 206.




Fig. 16. This horse has a very large (>2 cm long) rostro-laterally displaced 205 (wolf tooth) (arrowhead), that was causing biting problems. It had extensive lateral attachments to the premaxilla and is being removed using a bone chisel (C) which has been placed over the upper incisor plate of the speculum.

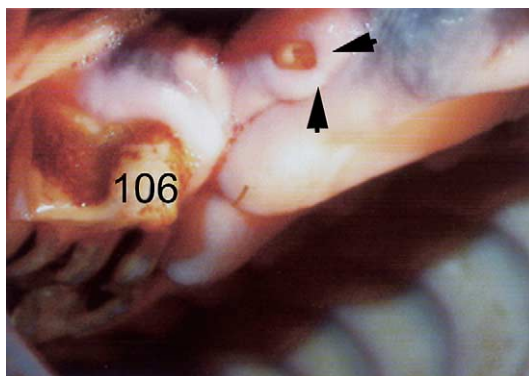


Fig. 17. This horse has the fractured remnants of a rostrally displaced “wolf tooth” (105) protruding above the alveolar level, which is surrounded by swollen mucosa (arrows). Unsuccessful attempts at wolf tooth extraction can sometimes leave such sharp protruding fragments that can cause more biting difficulties, than were present prior to the partial extraction. The adjacent 106 has a sloping rostral overgrowth.

swellings at these sites that cause biting problems (Fig. 17), that may not have been present prior to the partial extraction of these teeth.

## 8. Disorders of development and eruption of the cheek teeth

### 8.1. Retained deciduous cheek teeth

Abnormal retention of the remnants of the deciduous CT (termed “caps”) can occur in horses between two and 4.5 years of age. These deciduous teeth are normally shed at 2.5, three and four years of age, respectively, for the 06s, 07s and 08s (Sisson and Grossman, 1971), but there can be much individual variation in the timing of deciduous cheek tooth shedding. If the deciduous teeth are very loose or just partially retained by gingival attachment, they can cause short-term oral discomfort. Affected horses may display headshaking, quidding, resistance to the bit, and occasionally loss of appetite for a couple of days, until these loose teeth are shed. Such clinical signs in 2–4 year-old horses warrant a careful oral examination for evidence of *loose* deciduous teeth. If such teeth are found, they may be removed (Fig. 18), using a specialised ‘cap extractors’ or a long slim-bladed instrument. Even if not loose, some clinicians advise that temporary CT should be extracted, if the corresponding contra-lateral “cap” has been shed.

It has been alleged that the prolonged retention of “caps” may predispose to delayed eruption of the underlying permanent cheek tooth and also to the development of enlarged “eruption cysts” (“3- or 4-year-old bumps”) and thus lead on to apical infections (Barrairon et al., 1980). These swellings, beneath the developing apices of the permanent CT, occur more commonly on the mandible than maxilla. However another study

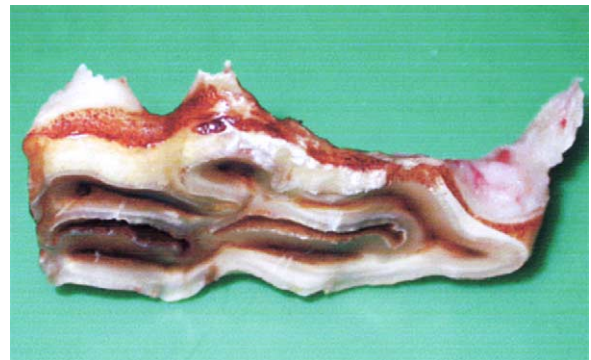

Fig. 18. This remnant of deciduous cheek tooth (606) (“cap”) was manually removed and shows a long, rostral spicule of root, which was embedded down the periodontal space. Trauma to the periodontium from such loose “cap” spicules and also tearing of partial gingival attachments can cause temporary pain and oral dysphagia in young horses.

found no evidence of retained deciduous CT in horses with mandibular apical infection – most which developed within months of eruption of affected teeth (Dixon et al., 2000b). Nevertheless, the presence of very enlarged eruption cysts on the mandible or maxilla, especially if unilateral, should prompt a thorough oral examination for the presence of retained deciduous CT.

However, the practice of methodically removing deciduous teeth at set ages will result in the premature removal of deciduous CT in some horses. Once the deciduous tooth is removed, the fleshy dental sac covering the underlying developing permanent cheek tooth is exposed and is then quickly destroyed by mastication. This will lead to loss of blood supply to the infundibula of the rostral three upper CT, where active cement deposition may still be occurring and so may possibly result in central infundibular cement hypoplasia and predispose to infundibular caries later in life. In conclusion, deciduous teeth should not be removed until they become digitally loose, protrude above the remaining occlusal surface, or the contralateral deciduous tooth has been shed.

### 8.2. Rostral positioning of the upper cheek teeth rows

As noted in the incisor section, a common dental abnormality in horses is a rostral positioning of the upper CT rows relative to their mandibular counterparts. Rarely, this abnormality can occur independently of incisor malocclusion. The presence of incisor overjet should always prompt a thorough examination of the rostral and caudal CT. Because the upper and lower CT rows are not in full contact in this disorder, localised dental overgrowths (colloquially termed “beaks” and “hooks”) develop on the rostral aspect of the upper 06s (Figs. 14 and 15) and these overgrowths may be pressed against the lips and cheeks by the bit and so cause biting problems. These overgrowths also restrict the normal, but variable, rostro-caudal mandibular movement (relative to the maxilla and premaxilla) associated with lowering and raising of the head (Carmalt, 2003), that may prevent smaller rostral 06 overgrowths from occurring. Feeding from the ground rather than from a raised hay net may also promote rostro-caudal mandibular movement and so help reduce such overgrowths. Smaller 06 overgrowths can be manually rasped level, but if large, motorised dental instruments will be required.

A similar overgrowth may also develop on the caudal aspect the lower 11s (Fig. 19), but due to the later eruption of these teeth in comparison to the 06s, possibly not until the horses are five to six years of age. These lower 11 overgrowths are frequently undetected unless a full dental examination is performed (Easley, 1999a). Additionally, true lower 11 overgrowths must be differentiated (e.g., by assessing crown height above gingival margin) from the anatomically normal, upward

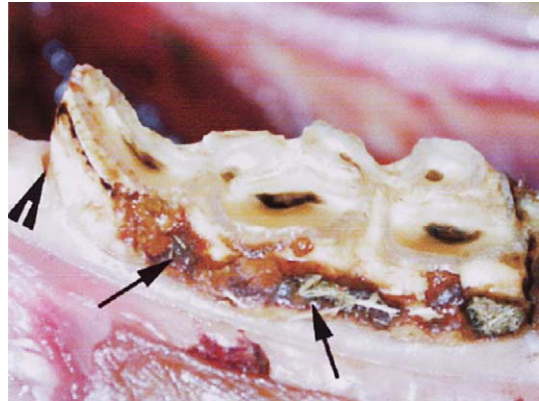


Fig. 19. This 411 has a small focal overgrowth of its caudal aspect. Such overgrowths are commonly associated with a rostral overgrowth of the upper 06s and incisor overbite. Peripheral cemental pitting and localised caries of unknown origin are also present, as is an abnormal periodontal pocket (sulcus) at the caudal aspect of this tooth (arrowhead).

sloping caudal CT occlusal surface (“curve of Spee”), which is especially marked in smaller breeds (e.g., Arabian and Welsh ponies). Lower 11 overgrowths can traumatise the adjacent oral mucosa during mastication, and if large enough, can even lacerate the hard palate and the greater palatine artery. Because there is very little room caudal to the lower 11s and the vertical ramus of the mandible, the soft tissue caruncle caudal to the lower 11s, and also the mandible, can be readily traumatised when manually rasping lower 11s. Consequently, sedation is often necessary to fully evaluate and carefully reduce larger lower 11 overgrowths.

If lower 11s are very overgrown, it may not be possible to place a rasp blade on their occlusal surface and the overgrowth may have to be ground on its medial (or lateral) aspects using the wide variety of powered dental instruments currently available (Scrutchfield, 1999b; Dacre et al., 2002). Manual instruments such as simple and compound ‘molar cutters’; cold chisels or percussion guillotines (that encircle these caudal 11 overgrowths) were previously used to remove such large dental overgrowths, but these risk fracturing the tooth and causing pulpar exposure. Such pulpar exposure is most likely to occur in younger horses (under 10 years) and in ponies with a marked “curve of Spee”. Iatrogenic dental fractures of the lower 11s, with pulpar exposure, can lead to cellulitis of the mandibular, oral and pharyngeal areas unless appropriate antibiotics are administered. These life-threatening oral and pharyngeal infections have been caused, particularly by untrained personnel attempting to remove real or perceived (i.e., “curve of Spee”) caudal lower 11 overgrowths.

### 8.3. Disparity in the length of the cheek teeth rows

A disparity between the lengths of the upper and lower CT rows (including due to the presence of a

supernumerary cheek tooth in one row) can result in overgrowths occurring unilaterally or bilaterally on the 06s or 11s (or supernumerary tooth) in both upper and lower CT rows. Such disparities may develop in older horses due to differences in the degree of crown to apex taper between different CT rows. Such rostral and caudal CT overgrowths should be reduced as previously described. Horses with asymmetric faces, (“wry nose”) even if very subtle, will also develop rostral 06 and caudal 11 overgrowths on *one* side of their mouth, as well as abnormal (diagonal) incisor wear (“slope-mouth”, “slantmouth”).

#### 8.4. *Diastema(ta)*

As noted earlier, the occlusal surfaces of the individual CT rows are normally compressed tightly together so that the occlusal surface of the six CT in each row function as a single grinding unit. Even with age, the progressively smaller reserve crowns usually remain tightly compressed at the occlusal surface, by further eruption of the angulated rostral and caudal CT. However, if spaces – termed *diastema(ta)* – develop between the CT, interdental food impaction will occur (Dixon et al., 1999b) (Fig. 20). The presence of sharp transverse overgrowths or accentuated transverse ridges directly opposite diastemata will selectively widen such diastemata and compress food into them. Carmalt (2003) has proposed that the terms *valve diastema* or *closed diastema* be used to differentiate these pathological diastemata from the normal diastemata present between the incisors (or canine teeth in males) and the CT (i.e., “bars of mouth”) or from a wide interdental space, e.g., where a cheek tooth has been lost.

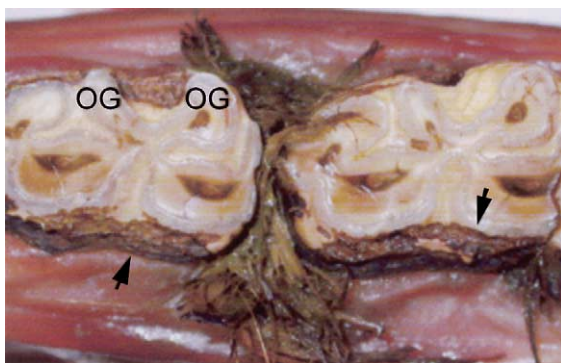


Fig. 20. This specimen shows marked diastema and deep food pocketing between two mandibular cheek teeth. There is also peripheral cemental caries present on the buccal aspect of these teeth (arrowheads). Some overgrowths (OG) are present on the lingual aspect of these teeth, particularly of the left-hand tooth. Because of the pain associated with such diastemata, horses may not masticate normally on the affected side and thus are predisposed to developing such secondary dental overgrowths.

The massive and prolonged forces of mastication in the horse will cause progressively deeper food impaction in wide interdental space (Fig. 20), which will later spread sub-gingivally to the lateral and medial aspects of the two affected teeth. This leads to a painful and usually progressive secondary periodontal disease with remodelling and lysis of the alveolar bone – that may even lead to extensive osteomyelitis of the supporting mandibular or maxillary bones, or if involving the upper 08s–11s, to an oro-maxillary fistula – with the maxillary sinuses becoming filled with food. CT diastema can be recognised by finding food fibres packed in small spaces between the CT just above the gingival margin, especially between the caudal mandibular teeth. Open mouthed radiographic evaluations of these spaces are the optimal method of assessment of this disorder (Easley, 2002; Barakzai and Dixon, 2003). Endoscopic examination of the mouth can also aid diagnosis (Simhofer et al., 2003).

Cleaning out periodontal pockets with manual dental picks, or using recently developed, water or compressed air picks allows short-term relief. Removal of overgrown transverse ridges opposite diastemata may reduce food impaction. Reducing the occlusal surface crown height on either side of the diastemata by 2–5 mm and similarly reducing the height of the opposing teeth at this same site may also be palliative. Feeding mechanically chopped forage is also palliative because short (e.g., <5 mm long) fibres will not become entrapped in diastemata. In younger horses, this diet may allow time for further eruption and compression of the CT row, *provided* the rostral and caudal CT have sufficient angulation (Barakzai and Dixon, 2003).

Specialised burrs have recently been developed to widen diastemata at the occlusal surface to help limit food trapping (Fig. 21) and are best used after radiographic evaluation (open-mouth projections) of diastemata to help reduce the risk of iatrogenic pulpar exposure during such procedures. Such instruments show promise but have not yet been critically evaluated in the long-term, especially in younger horses. If only

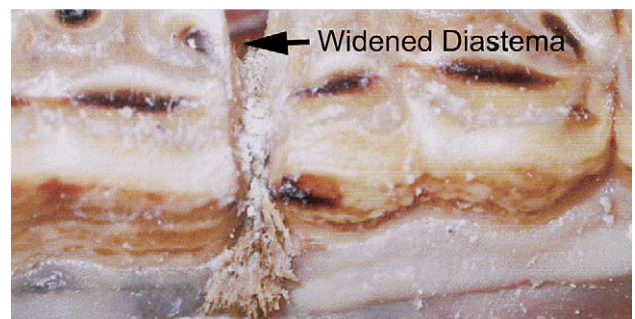


Fig. 21. This mandibular specimen shows a diastema between two mandibular cheek teeth, with extensive food impaction, which has been partially widened using a diastema burr (Powerfloat).

one or two very painful diastemata are present, extraction of a tooth on one side of a diastema can be effective.

### 8.5. Displacement of the cheek teeth

Two different causes of cheek tooth displacement are recognised in horses (Dixon et al., 1999b). In most severe cases, especially in younger horses, the displacements appear to be due to overcrowding of the dental rows during eruption. This *developmental* CT displacement is often bilateral and rotation of the displaced tooth is occasionally present, more so when maxillary CT are involved. Gross overgrowths will develop on areas of the displaced and the opposing teeth that are not in occlusal contact. Developmentally displaced CT usually have diastemata between the displaced and adjacent CT which allows painful food pocketing (Fig. 22). In some cases, very wide diastemata occur, which would suggest that abnormal positioning of the developing tooth bud, rather than dental overcrowding was the cause of the displacement.

*Acquired* CT displacements (usually medial displacements of the lower 10s and 11s) frequently develop in older horses (Fig. 23). They are usually associated with lesser degrees of displacement and smaller overgrowths – the latter indicating that the displacements were recent. The cause of these acquired CT displacements is unclear, especially as they usually involve one or two teeth in a row, that all *appear* to be undergoing the same level and direction of forces during mastication. Some acquired displacements may be predisposed to by abnormal angulation of the CT occlusal surfaces (e.g., shearmouth). Pre-existing periodontal disease may also pre-dispose to displacement, by reducing support against the normal masticatory forces.

Abnormally protruding areas of displaced CT and less commonly, secondary overgrowths on opposite teeth, can lacerate the cheeks and tongue and cause

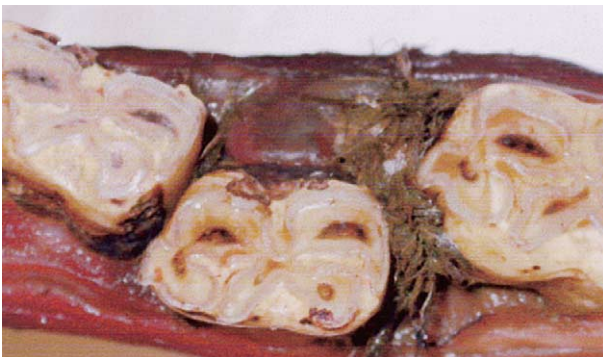


Fig. 22. The middle tooth in this mandibular specimen (with marked postmortem mucosal darkening) has marked medial (lingual) displacement with extensive secondary diastemata, particularly at its rostral aspect. This degree of cheek teeth displacement is usually developmental, e.g., due to dental overcrowding.

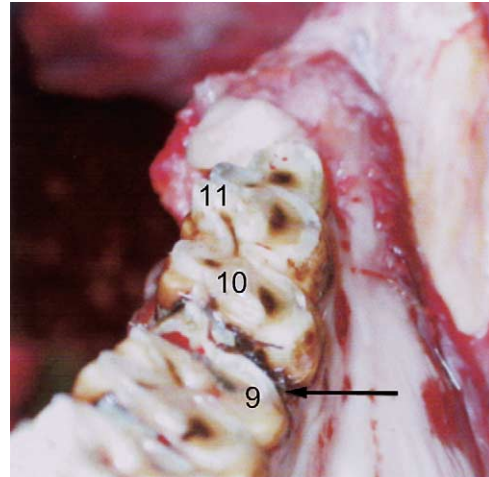


Fig. 23. The 310 (10) and 311 (11) of this specimen have about 5 mm of medial displacement and also have increased occlusal surface angulation – as compared to the remaining cheek teeth. There is also a diastema between 309 (9) and 310 (arrow). This is most likely an acquired displacement of 310 and 311.

bitting and quidding problems. However, deep periodontal food pocketing due to concurrent diastemata (Fig. 22) is usually the source of most severe quidding problems, and such quidding may persist after the protruding areas of displaced teeth are ground down.

Smaller abnormal protrusions or overgrowths associated with displaced CT can be removed with a hand rasp (float), but larger areas will require motorised reduction. Food packing in diastemata should be cleaned out with an appropriate pick. If very extensive food pocketing is present these diastemata can be mechanically widened and overgrowths on the opposing teeth ground down. Finally, displaced teeth can be extracted, especially in older horses and when loosened by periodontal disease. Such extractions can be performed per os in the sedated horse, especially in long-standing cases with extensive periodontal ligament damage and an excellent response usually follows.

### 8.6. Supernumerary cheek teeth

Supernumerary CT (i.e., the presence of more than six CT in a row) are not uncommon in horses. The supernumerary teeth may be abnormally large and irregularly shaped, as if formed from two or even three immature teeth, i.e., are connate teeth. They most commonly develop at the caudal aspect of the CT rows, especially the maxillary rows (Dixon et al., 1999b) and may not erupt until horses are over five years old. Because of their often-irregular shape, and due to induced overcrowding and displacement of the affected CT row, periodontal food pocketing often occurs between supernumerary and adjacent teeth, with resultant pain (and quidding). Occasionally, deeper infections with

periapical infections or even an oro-maxillary fistula (*without* apical infection of adjacent teeth) can occur. Additionally, if the supernumerary teeth develop in just one row, and are thus unopposed, they will eventually develop large overgrowths. Where deep periodontal food pocketing or apical infection are present, supernumerary CT should be extracted. This should be performed per os if possible, especially for caudal maxillary supernumerary teeth whose apices will often be very caudally angulated and lying beneath the orbit. In cases of supernumerary CT without significant periodontal disease, burring of overgrowths is sufficient.

### 9. Disorders of wear of cheek teeth

Due to the differential wear between the harder enamel and softer cementum and dentine, some enamel folds normally protrude on the CT occlusal surface, including medially on the mandibular and laterally on the maxillary CT (Fig. 24). There is subjectivity in determining what size of enamel protrusion constitutes an overgrowth. The development of large enamel overgrowths are claimed to be largely due to domestication with the associated feeding of concentrates, which markedly reduces the time a horse chews its food, which is normally up to 18 h/day in some outdoor horses (Leue, 1941; Becker, 1962). The feeding of high-energy grain and processed food also promotes a more vertical than (normal) lateral mandibular movement and further promotes the development of overgrowths (Leue, 1941). However, the authors annually monitor some permanently outdoor Exmoor ponies that never receive concentrates and observe that some develop such enamel

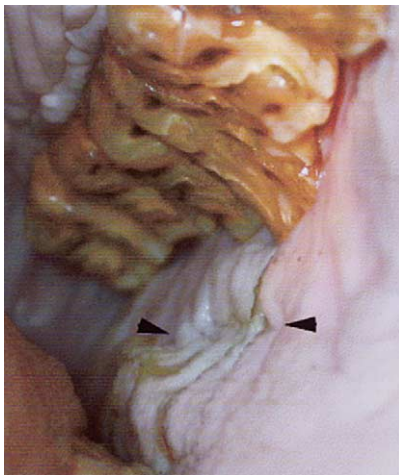


Fig. 24. Overgrowths on the buccal aspects of these maxillary cheek teeth have caused ulceration of the cheeks (arrows). One cheek tooth (209) is wider than the adjacent teeth and has particularly large overgrowths on its buccal aspect.

“overgrowths”, especially of the buccal aspect of their caudal maxillary CT.

A major aim of equine dentistry is to prevent acquired dental overgrowths from becoming large by routine and effective dental rasping (floating). If these dental overgrowths are neglected they can eventually involve the entire occlusal surface, that may then become a steeply angled (e.g.,  $>45^\circ$ ) surface termed ‘shear mouth’. In the presence of these large dental overgrowths, mechanical obstruction will now (in addition to possible pain from soft tissue lacerations) prevent the normal side-to-side mandibular movements, and mastication will become even less effective, in a self-perpetuating fashion.

Food stagnation may now occur at the gingival margin, mainly on the lateral (buccal) aspect of the mandibular CT, due to reduced oral movement of food and saliva. In turn, this will cause secondary periodontal infection, leading to increased oral pain, quidding and halitosis. As dental eruption is dependent on a healthy periodontal membrane, teeth that have marked periodontal disease may erupt more slowly than teeth with healthy periodontal membranes. This may be one factor in leading to the occlusal surface of the CT developing an uneven or undulating occlusal surface in a rostro-caudal direction, termed “wave mouth”. Concurrent deep periodontal disease, due to food pocketing, can lead to premature tooth loss, especially in older horses, which have short reserve crowns.

Following loss of a cheek tooth, the opposing tooth will erupt more rapidly, e.g.  $>5$  mm of eruption/annum (double the normal rate), leading to the dental irregularity termed ‘stepmouth’, because these overgrowths are initially rectangular in appearance. However, depending on the degree of latero-medial and rostro-caudal mandibular movement present in these horses, these rectangular overgrowths may later become rounded or triangular in appearance. If untreated, these abnormalities of wear are progressive, leading to restriction of normal food grinding due to oral pain and mechanical impairment, as previously described, with resultant quidding, halitosis and weight loss. Bi-annual rasping of overgrown teeth can prevent such overgrowths (Greene, 2000).

At some stage in their life, many horses will develop individual, latero-medial (transverse) overgrowths along their CT rows, including at the sites of their (ca. 12–13) normal transverse ridges (cusps), especially over their caudal CT. These transverse elevations have been termed “exaggerated” or “accentuated” transverse ridges”, even when not at the site of anatomical transverse ridge. Such abnormal areas of growth should be reduced judiciously. However, some operators reduce all normal transverse ridges without scientific justification, claiming that these ridges restrict rostro-caudal mandibular movement, which allegedly causes temporo-mandibular

joint pain. These normal transverse ridges have evolved to increase the occlusal surface area of the CT.

Excessive rasping (especially with power instruments) greatly reduces or even removes normal transverse ridges and enamel ridges, resulting in a flat and smooth occlusal surface, resulting in inefficient feed utilisation. Within a month or so however the occlusal table will again develop raised enamel ridges and return to more efficient food mastication. Such excessive rasping will greatly shorten the functional lifespan of the CT. In the short term, such excessive rasping may well expose sensitive dentinal tissues, including odontoblast processes (Kempson et al., 2003) and cause pain and quidding.

Other larger, more focal dental occlusal irregularities are believed to be due to differential eruption of opposite teeth. For example, the maxillary 10s may erupt at nine months of age while the mandibular 10s erupt six months later, with the initially erupted upper CT becoming “dominant” and maintaining or even increasing this advantage throughout life (Becker, 1962) (Fig. 25). In other cases, the presence of infundibular cemental caries may mechanically weaken upper CT and so predisposes them to increased wear, with resultant overgrowths developing on the opposing mandibular CT. Regardless of aetiology, large focal overgrowths may restrict normal mastication and so eventually predispose to more generalised overgrowths, such as “wavemouth” and “shearmouth” (Becker, 1962; Scrutchfield, 1999a; Dixon et al., 2000a). Early identification and treatment of such focal overgrowths may result in a normal occlusal surface in the long term. No obvious explanation is available for markedly abnormal occlusal wear patterns in some horses, such as general overgrowths (“steps”) of lower 11s, protuberant lower 06s; and 08s/09s wave-like overgrowths. This is an important area requiring research.

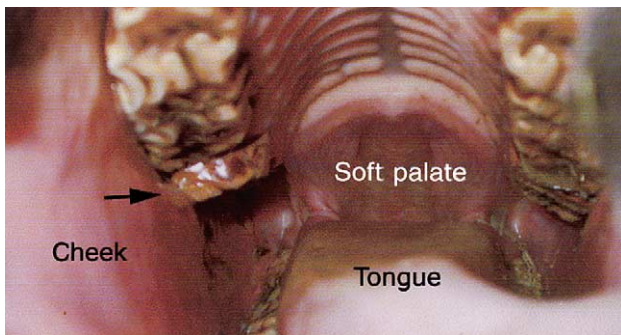


Fig. 25. This four-year-old horse has localised overgrowths of 110 (arrow) and less so of 210 (“protuberant teeth”). These overgrowths may have arisen because of premature eruption (<2 years of age) of these two teeth or conversely, due to delayed eruption (e.g., at 2.5 years of age) of the opposing teeth (310 and 410), thus allowing these overgrowths to develop.

Treatment of CT overgrowths includes: judicious reduction of major overgrowths, preferably using a motorised instrument (Fig. 26), followed by careful rasping of these teeth to remove any remaining sharp edges. If grossly overgrown, teeth should be reduced in stages, e.g., at three to six monthly intervals, to prevent pulpar exposure. Digitally loose teeth can be extracted orally using equine CT extraction forceps in standing sedated horses. In older horses especially, some loose, overgrown CT (Fig. 27) can re-attach themselves following removal of large overgrowths (and possibly even reducing loose teeth by a few mm below the normal occlusal surface) to take them out of occlusion for a few months. Removing mechanical impediments to lateral masticatory movement and painful dental overgrowths will promote normal masticatory movements and help restore normal oral food and salivary flow. As noted, the aim of routine dental care should be to prevent the development of such end-stage disorders by regular, 6–12 monthly dental inspections.

### 9.1. Smooth mouth

“Smooth mouth”, i.e. where CT occlusal enamel ridges are absent or reduced (Fig. 27) is the normal end-

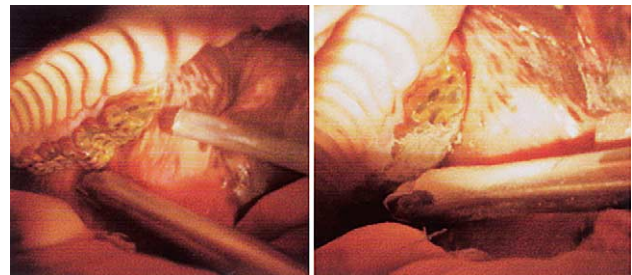


Fig. 26. On left: Intra-oral view of overgrowths of the caudal aspect of 207 and most of 208. A mechanical dental burr (LeClair) is about to be used to reduce these overgrowths (note vacuum piping). On right: Following mechanical reduction of these 207 and 208 overgrowths.

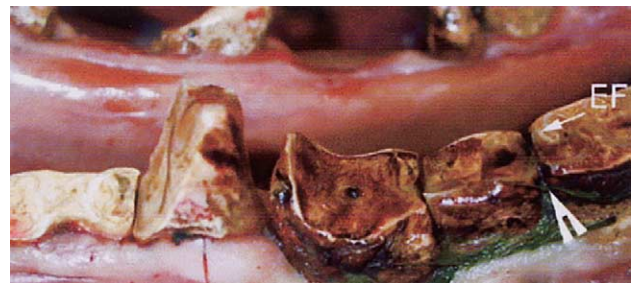

Fig. 27. Some of the teeth of this aged horse have “smooth mouth”, i.e., absence of any significant enamel folds (EF) on their occlusal surface. Some also have a concave occlusal surface. Some focal overgrowths are also present, due to the loss of the opposing teeth. Senile diastema with food trapping (arrowhead) is also present.

stage of physiological wear (attrition) of the occlusal surface in older horses (Lowder and Mueller, 1998). Equine CT wear at ca. 2–3 mm wear per annum and so many equine CT are worn away by 25–30 years of age. Some horses will prematurely develop smooth mouth, due to limited infolding of peripheral enamel, absent or shortened upper CT infundibula, with the softer dentine and cementum in these teeth being un-protected by sufficient harder enamel (Dixon, 2002). Such teeth may develop smooth and hollow occlusal surfaces. Teeth with just cementum or dentine remaining are ineffective at masticating fibrous food. Once all enamel has been worn away in the crown (clinical and reserve), the remaining dentine and cementum are rapidly worn away. Later, the individual roots will become exposed and will display the characteristic hypercementosis of aged equine teeth.

### 10. Periodontal disease

Unlike brachydont animals, primary periodontal disease (i.e., inflammation of the gingiva, periodontal ligaments, cementum and alveoli) does not appear to be a significant problem in the horse (Dixon et al., 2000a), although historically it was claimed to be the major equine dental disease and was even termed “the scourge of the horse” (Colyer, 1906). It is likely that this previously recorded periodontal disease was in fact secondary to undiagnosed diastemata or CT displacements (Figs. 20–23), because some of Colyer’s early photographs of periodontal disease published by Miles and Grigson (1990) show *secondary* periodontal disease clearly associated with diastemata. During the eruption of the permanent teeth, a transient inflammation of the periodontal membrane and adjacent gingiva occurs in many horses and can be recognised by a marginal reddening of the gum around the erupting teeth. Due to the prolonged eruption and continuous development of new periodontal fibres in the horse, equine periodontal disease is not necessarily irreversible (as is the case with brachydont dentition) – as with further equine dental eruption, new periodontal ligaments will develop. Most clinically significant periodontal disease in the horse occurs secondarily to dental overgrowths and malocclusions and correction of the primary problem may resolve the periodontal disease, unless it is very advanced.

Due to a combination of age-related diastema and abnormalities of wear (especially shearmouth and wavemouth) many older horses suffer from secondary periodontal disease (Fig. 27). Treatment of secondary periodontal in these cases includes promotion of normal masticatory activity by removing painful and mechanically restrictive dental overgrowths and so promoting free lateral and possibly rostro-caudal jaw movement;

along with oral extraction of very loose or diseased teeth. With dietary management (e.g., feeding finely chopped forage), such old horses can be satisfactorily maintained in good health after loss of most of their teeth.

### 11. Traumatic disorders of cheek teeth

Swellings of the maxillary and more so of the mandibular bones can be caused by external trauma, usually due to kicks. In the young horse, traumatic mandibular fractures will inevitably cause some damage to the CT reserve crowns that occupy much of this bone (Greet, 1999). In most cases of non-displaced fractures, conservative therapy (one to two weeks antibiotic therapy and feeding a soft diet for six to eight weeks) will be adequate, with the undamaged hemimandible acting as an effective splint. Even if external sinus tracts do develop, it is worthwhile persevering with conservative therapy, until radiographic changes (using a metallic probe in any sinus tract) confirm the presence of definitive dental infection. Extraction should be delayed for some months, to minimise the chances of re-fracturing the mandible.

Bit-induced injuries to the mandibular interdental space (bars of mouth) can occur due to very excessive force with a bit or chifney. In most cases, a superficial periostitis or sequestration of the mandibular cortex will occur (Greet, 1999). However, pathological fractures of the mandible and also deeper mandibular infection may lead apical infection of the lower 06s, which may have to be extracted (Dixon et al., 2000a).

### 12. Idiopathic cheek teeth fractures

Fractures commonly occur in the CT, mainly the upper CT, in the absence of known trauma (Dacre, 2004). In most cases these are lateral sagittal “slab” fractures through the two lateral pulp cavities (Fig. 28). The fracture site later becomes filled with food, thus laterally displacing the smaller portion, which may then cause buccal laceration. Removal of the smaller loose fragment with forceps, and rasping the sharp edges of the adjacent teeth will usually resolve the clinical signs. Extraction is not indicated unless clinical evidence of periapical infection (maxillary swelling, sinusitis) occurs. Less commonly, midline, sagittal fractures of the maxillary CT occur (Dacre, 2004). These are believed to be secondary to advanced infundibular caries (Klugh et al., 2001) (Figs. 29 and 30). Deep-seated infections of the alveolus and even sinus infections may accompany this latter type of fracture in younger horses. Removal of grossly displaced (Fig. 31) or mobile fractured dental fragments is usually adequate, but complete extraction



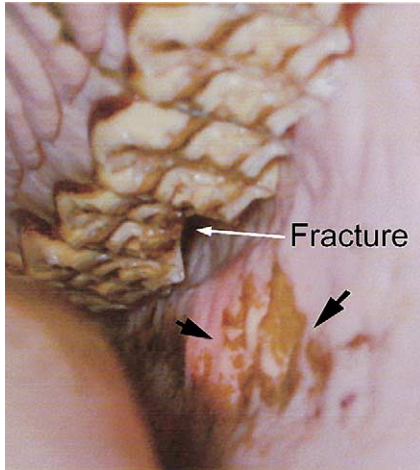


Fig. 28. This 209 has suffered a “slab” fracture through the two lateral pulp cavities, with loss of the lateral fragment. The newly exposed sharp corners on the buccal aspects of 208 and 210 have caused buccal ulcerations (arrows).

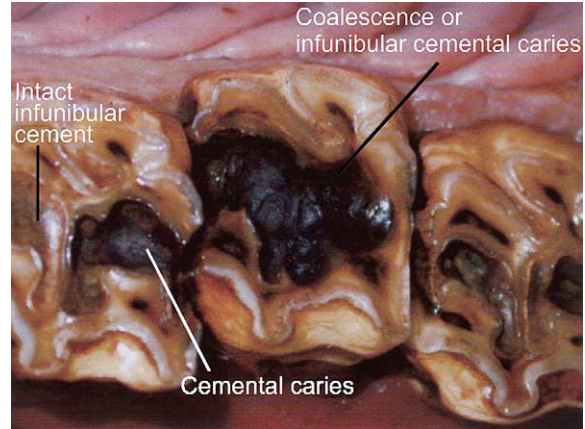


Fig. 30. These maxillary cheek teeth show medial (palatal) displacement of the central tooth. This tooth also has advanced caries of the cement of both infundibula and of the adjacent enamel and dentine that has coalesced (sagittally) across the middle of the tooth. Such teeth are prone to midline (sagittal) fractures. The adjacent teeth also show infundibular cemental caries.

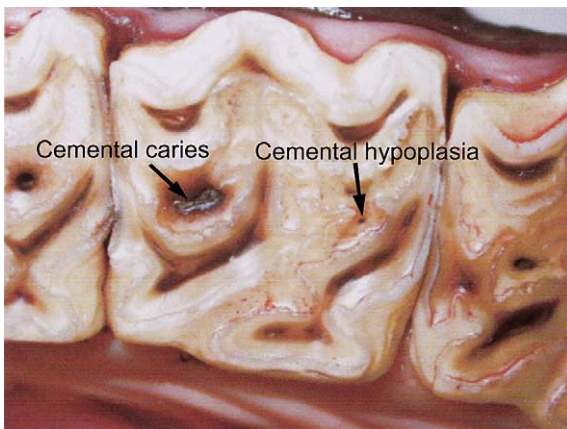


Fig. 29. This maxillary cheek tooth has localised caries of its caudal infundibulum (on the left side) and also has cemental hypoplasia (i.e., a large vascular channel remnant) of its rostral infundibulum.

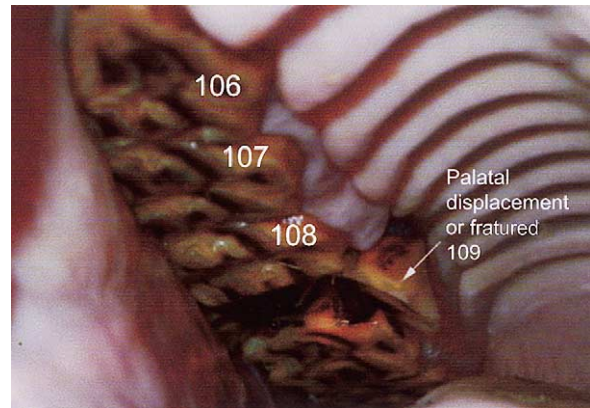


Fig. 31. Intra-oral view of a midline sagittal fracture of 109, with palatal displacement of the medial fragment.

of the fractured tooth (Fig. 32) is indicated if both fragments are loose. Sinus irrigation is also required in the presence of concurrent dental sinusitis.

### 13. Apical infections of cheek teeth

Apical infections of CT (in adult horses, such infections can also be accurately termed tooth *root* infections) are a significant problem, especially in younger horses, where the infections inevitably involve the supporting bones or paranasal sinuses. The cause(s) of these periapical infections in upper CT was previously believed to be a sequel to food accumulation and fermentation deep in the sites of the central vascular channel of the infundibular cement – the latter developmental disorder being termed central infundibular

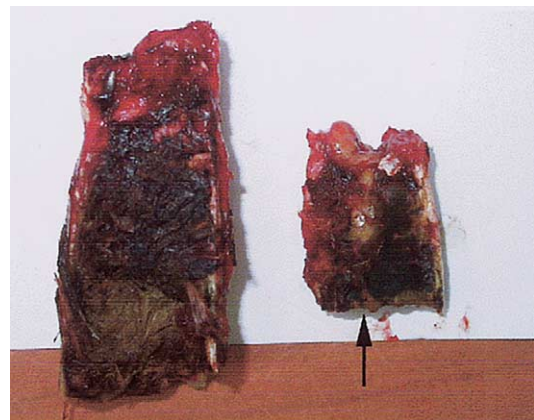


Fig. 32. An extracted, sagittally fractured maxillary cheek teeth (209), possibly predisposed to by advanced infundibular caries with coalescence of the two infundibula. This fracture lead to food impaction in the fracture site (some food still remaining) that caused lateral (buccal) displacement of the lateral side of the fractured tooth, with later loss of its clinical crown (arrowhead).

cemental hypoplasia (Kilic et al., 1997b). Such caries of the existing cement has been termed ‘infundibular necrosis’ although the cement in the infundibula has no blood supply after eruption. A more accurate term for this localised disorder is infundibular cemental caries. It was believed that the cemental caries extended through the enamel walls and the adjacent dentine and caused pulpar infection in some cases. Localised cemental caries is however, very common within these infundibula and is usually innocuous. Additionally, all of the incisors have such infundibular enamel cups (albeit shallower) and yet seldom develop periapical infection. More recent studies (Dacre, 2004) have shown this mechanism of maxillary CT pulpar infection to be rare. Caries is rare at other sites in equine teeth. Peripheral cemental caries (Figs. 19 and 20) is usually of little significance but rarely it can involve deeper dental structures (Fig. 33). Overall, caries is a minimal cause of equine apical infection (Dacre, 2004).

An imbalance between CT wear and the formation of secondary dentine (that normally prevents the pulp cavity from becoming exposed) can also occur in horses. If occlusal wear exceeds secondary dentine production this can lead to exposure of, and in some cases deep food impaction, and infection of the pulp cavity and may even lead to apical infection of both upper and lower CT (Dacre, 2004). However, with apical infection of *any* cause that leads to pulpar death, the odontoblasts which line the periphery of, and are nourished by the pulp, will also die and thus all secondary dentine production will cease. Such teeth will usually continue to erupt because the periodontal ligaments are largely unaffected by the usually localised apical infection, as they receive their blood supply via the alveolar bone. However, the existing secondary dentine present over all of the pulp cavities will eventually be worn away, leading to exposure of all the pulps. The fact that many apically infected CT have multiple pulpar exposures suggests that these pulpar exposures are *secondary* to a pre-existing apical infection (Fig. 34).

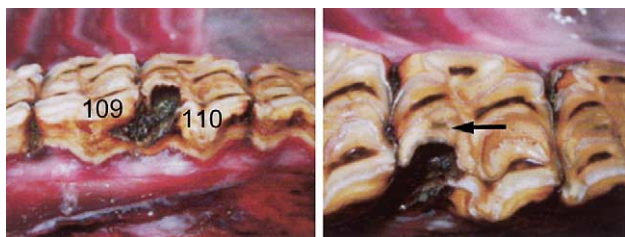


Fig. 33. The maxillary cheek tooth on right (110) has caries of the peripheral cementum, enamel and dentine of its rostro-lateral (buccal) aspect, which has extended medially into an adjacent pulp cavity (pulp cavity No. 1). The caudal infundibulum (arrow) shows some localised central infundibular cemental caries. The tooth on left (109) has focal peripheral cemental caries. This caries may have started at the interdental space between 109 and 110.

A bony distension of the mandible, known as an ‘eruption cyst’, may surround the apices of the rostral permanent mandibular CT (07s and 08s) when they erupt at three and four years of age, respectively. These ‘eruption cysts’ can cause considerable focal distension and thinning of the underlying mandibular bone. In the lower CT, periapical abscessation most commonly involves the 07s and 08 and often develops within 6–12 months of tooth eruption (Dixon et al., 2000b). Initially, this infection is confined to the periapical region. Vertical impaction, overcrowding of teeth, certain mandibular conformations and deciduous teeth retention may predispose to the presence of large eruption cysts, which more commonly occur in ponies. In a minority of cases the eruption cyst may erode through the mandible leading to exposure and infection of the underlying tooth (O’Connor, 1930). In its early stages, the infection may remain confined to the affected apex and adjacent periapical tissues, and the main portion of the large common pulp (a common pulp is present in immature CT) may remain vital. At this early stage prolonged antibiotic therapy may be of value.

It seems most likely that the majority of CT apical infections are due to anachoresis, i.e., blood or lymphatic borne bacterial infection of possibly devitalised apical pulp – possibly predisposed to by vertical impaction of these teeth (Dacre, 2004). More complete reviews of the potential aetiologies of upper and lower CT apical infections are given by Crabill and Schumacher (1998), Mueller and Lowder (1998), Dixon et al. (2000b) and Dacre (2004).

If the apical infection progresses, the pulp and calcified dental tissues adjacent to the apices will become infected. At this stage removal of the infected pulp and

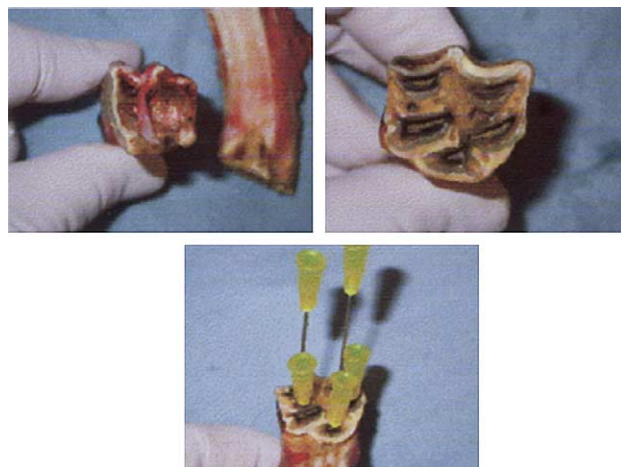


Fig. 34. This young cheek tooth (110) was extracted because of chronic apical infection with sinusitis. Food particles are apparent in the large pulp chambers (left Fig.). The occlusal surfaces show some pitting and discoloration of their secondary dentine areas (right Fig.) that were shown to be due to pulpar exposure of all five pulp chambers (bottom Fig.).

adjacent infected tissues is required. Endodontic (root canal) therapy, or more usually dental extraction may now need to be performed. The clinical signs of apical infection have been described earlier in this paper and include swelling and possibly discharging tracts of the mandible and rostral maxillary areas, respectively, for mandibular and rostral maxillary CT; and nasal discharge for sinusitis secondary to apical infection of the more caudal CT.

A thorough clinical (including intra-oral examination with a mouth gag) and radiographic evaluation of the case (especially latero-oblique projections) should always be undertaken, first, to absolutely confirm that a tooth needs to be extracted and second, to identify *which* tooth is diseased (Dixon, 1997a; Easley, 1999c) (Fig. 35). The interpretation of equine dental radiographs is often difficult, especially in the early stages of infection in young CT, where the presence of “eruption cysts” can closely mimic the radiographic appearance of apical infection (Gibbs, 1999). Sometimes, even experienced clinicians may not initially be able to determine clinically or radiographically, whether a cheek tooth has an apical infection or not. If an external sinus track is present, e.g., as occurs with many mandibular, and rostral (06–08) maxillary CT infections, it is essential to obtain radiographs with a metallic probe in situ, to define the relationship of the tract to the suspect apex. This procedure will also give anatomical landmarks, if the infected tooth is later to be extracted by repulsion.

Scintigraphy is of value in equivocal cases (Boswell et al., 1999; Weller et al., 2001; Archer et al., 2003b). Although the developing apices of normal CT will have increased uptake of radio-nucleotide (Archer et al., 2003a), much greater uptake will occur with apical infections. When available, other advanced imaging systems such computerised tomography (CT) or magnetic

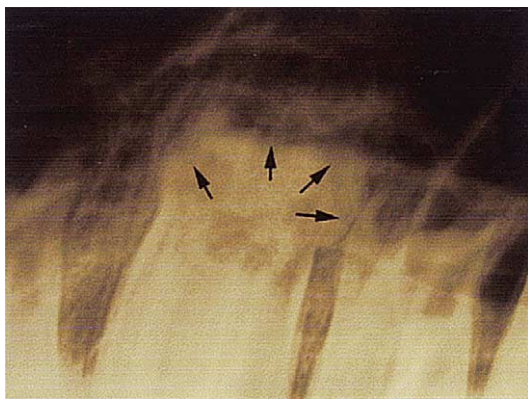

Fig. 35. Radiograph of the apical aspect of a maxillary cheek tooth with long-standing, relatively non-destructive, apical infection. Note the dumb-bell shaped, reactive hypercementosis of its apical area (arrows) with no evidence of a lamina dura (LDD) or periodontal space (PS) at this apical area. Because this swollen apex was bigger than most of the alveolus, this tooth was difficult to orally extract.

resonance imaging (MRI) can also give valuable diagnostic information (Tietje et al., 1996; Tucker and Farrell, 2001).

#### 14. Extraction and endodontic treatment of cheek teeth

Extraction of equine CT is a major surgical procedure with many possible immediate and delayed serious sequelae and consequently, this procedure should never be undertaken lightly (Dixon, 1997b; Easley, 1999c; Lowder, 2003). If any doubt remains concerning whether a cheek tooth is infected or not, conservative treatment should be undertaken rather than extraction; including antibiotic therapy (e.g., two weeks of oral trimethoprim and sulphonomide and/or metronidazole) for suspect mandibular or rostral (06–09) maxillary apical infections (Dixon et al., 2000b). Maxillary sinus trephination and irrigation, and antibiotic therapy should be employed for suspect caudal maxillary CT apical infections (Tremaine and Dixon, 2001b). Failure to respond to the above conservative therapy should prompt a further clinical and radiographic evaluation for dental infection – with serial radiographs sometimes being diagnostic. Only when definitive evidence of dental infection is present should dental extraction be considered.

##### 14.1. Repulsion

The traditional method for extracting equine CT has been repulsion of the diseased tooth under general anaesthesia (Easley, 1999c). This procedure carries all of the inherent expense and risks of equine general anaesthesia and is also associated with a high level of post-operative complications (Pritchard et al., 1992; Easley, 1999c; Dixon et al., 2000b). A surgical window is made close to the infected apex, e.g., on the ventral mandible for mandibular CT repulsion or a rostral maxillary bone window to repulse upper 06–08s. Larger (e.g., 5 cm<sup>2</sup>) caudal maxillary bone flaps can be used to perform a sinusotomy to allow inspection of the apices of the more caudal maxillary CT and then to allow their repulsion if apical infection is confirmed. Most CT apical infections occur in younger horses, and the infection is usually locally confined to the apical area of the tooth. Consequently, the remaining extensive and healthy periodontal membrane requires great mechanical force to be broken down.

Intra-operative radiographs should always be obtained following repulsion, unless the surgeon is certain that the tooth has been fully removed. Having ensured the alveolus is free of debris, the oral (occlusal) aspect of the alveolus should then be sealed, for example, with an acrylic or dental wax plug following mandibular or rostral maxillary CT repulsions. The surgical site used for repulsion of rostral maxillary or mandibular CT

should be left open to drain. It is worthwhile irrigating these wounds with very dilute iodine solutions or saline for a few days, especially if they remain very purulent or malodorous. Following repulsion of caudal maxillary CT, the maxillary bone flap should be closed and a separate small (e.g., 10 mm diameter) trephine hole should be made into the ipsilateral frontal sinus to allow post-operative irrigation of the interconnecting, infected maxillary sinus. When infected CT lie in the rostral maxillary sinus, the maxillary septum should be broken down to facilitate post-operative sinus lavage. The affected sinus should be irrigated twice daily, with, e.g., 5 L of very dilute iodine solution, for a week or so, or until the lavage fluid runs clear. Broad-spectrum antibiotics should also be administered for three to four days following all dental repulsions.

Complications commonly occur following repulsion of apical infected CT from younger horses, because much immediate and delayed damage occurs to the alveolar and supporting mandibular or maxillary bones during repulsion. Some studies have shown that over 50% of horses having maxillary CT repulsion will require a second surgery, usually to curette dental or alveolar sequestrae from non-healing alveoli, with lesser post-operative problems following mandibular CT repulsion (Pritchard et al., 1992; Dixon et al., 2000b).

#### 14.2. Lateral buccotomy technique

The lateral buccotomy technique utilises a lateral surgical approach directly through the skin, sub-cutaneous tissues and periosteum into the affected alveolus (Lane, 1997). The technique is most suitable for extraction of the rostral (06s–08s) upper and lower CT. The dorsal branch of the dorsal buccal nerves and the parotid duct should be identified and isolated if they lie in the surgical site. Using a bone burr, the lateral wall of the alveolus is then removed. The full length of the crown of the exposed tooth is sectioned longitudinally with the burr and extracted in pieces. The coronal aspect of the alveolus is then plugged with dental wax and the alveolus is packed with a gauze bandage, which is gradually withdrawn through a small stab adjacent to the surgical site. Iatrogenic buccal nerve damage leading to nasal paralysis, and also parotid duct damage, has been reported with this technique (Boussauw, 2003). In athletic animals particularly, the former sequel is a disaster. Prolonged anaesthesia is also required for this technique which is a further disadvantage.

#### 14.3. Oral extraction of cheek teeth

There has been a recent revival of the old techniques of oral CT extraction (Tremaine, 1997; Easley, 1999c) and Tremaine (2004) has comprehensively reviewed this technique. This technique has the great advantage of

being performed in the standing horse and thus removes the expense and risk of general anaesthesia. Additionally, it does not require surgery of the supporting bones and consequently, post-operative sequelae are greatly reduced compared to dental repulsion (Dixon et al., 2000b). The current availability of safe and effective sedatives and analgesics has been a major reason for the revival of the oral extraction technique, as the instrumentation has remained largely unchanged for a century.

A prerequisite for oral extraction of equine CT is excellent restraint of the horse. This can be achieved by a combination of  $\alpha$ -2-agonists with butorphanol or morphine. Local anaesthesia can also be beneficial and is most readily performed on the mental nerve when extracting lower CT. The horse is best restrained in stocks and it is useful to have a headstand or a suspended dental halter to help elevate and stabilise the head. A good headlight is also required, especially when extracting caudal CT, to absolutely ensure that the right tooth is being removed. In many horses, the medial (palatal) aspect of the upper CT contains very little exposed crown, with the gum margin in some horses lying just 2–3 mm below the occlusal surface. If horses have a shearmouth (increased angulation of occlusal surface) no clinical crown may be present on the medial aspect. In such cases especially, the gingiva is detached from around the affected tooth using a long handled metal dental pick, to the level of the alveolar crest, particularly medially. This usually exposes enough dental crown to allow extraction forceps to be firmly applied on the palatal side of the affected tooth.

A “molar separator” instrument should now be inserted in the interdental spaces, rostral and then caudal to the affected tooth, to cause slight rostro-caudal tooth movement. Extraction forceps are then firmly attached to the crown of the diseased tooth, which is then gently rocked from side to side. After a variable period (usually 15–75 min), depending on the extent and health of the periodontal membranes, a “squelching” sound is heard. Increased movement of the forceps can now also be appreciated and foamy blood can be seen at the gingival margin. After possibly a further 15–30 min the tooth will become digitally loose. At this stage, a fulcrum is placed on the occlusal surface of the tooth rostral to the infected tooth. Vertical pressure is now exerted on the forceps, drawing the affected tooth intact from the alveolus, possibly in a medial direction if a large reserve crown is present (Fig. 36). If no external draining tract is present, the empty alveolus can simply be plugged with a swab containing dilute iodine or metronidazole. The swab should be checked and possibly replaced 2–3 weeks later, but may be displaced by granulation tissue by that time.

If an external sinus tract is present, the tract can be gently curetted and will usually spontaneously heal

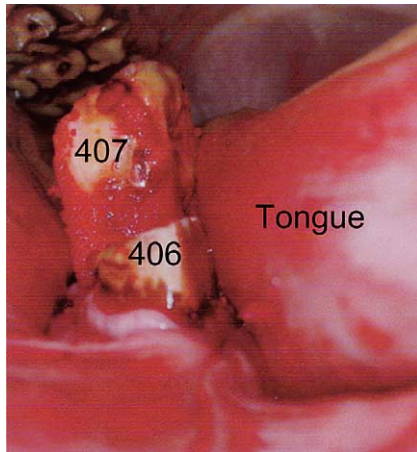


Fig. 36. The final stages of oral extraction of an apically infected 407 in a young horse. The tooth is now digitally loose and has been elevated 3–4 cm into the oral cavity.

within a few days. If extensive bony changes are present deep in the sinus tract, it may be advisable to seal off the oral aspect of the alveolus with dental wax or acrylic (Fig. 37) and to irrigate the sinus tract with dilute iodine for couple of days.

Oral extraction of the CT can also be performed on horses with infection of the caudal maxillary CT, which have a secondary dental sinusitis. Following dental extraction, the sinus should be trephined (e.g., through a small trephine opening into the adjacent ipsilateral frontal sinus) and irrigated as previously noted, for about seven days. Many cases with infection of the 08s and 09s with infections of the rostral maxillary sinus will have destruction of the maxillary septum and thus frontal and caudal maxillary sinus lavage will also lavage the rostral maxillary sinus. If the empyema is localised to the rostral maxillary sinus, this sinus will need

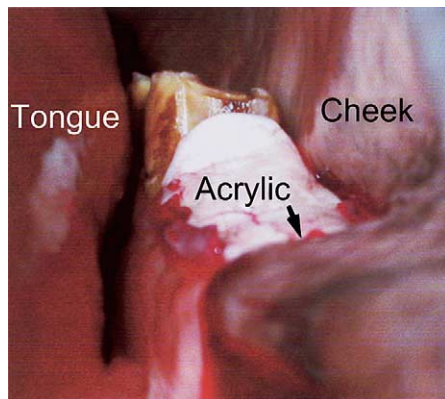


Fig. 37. An acrylic (bone cement) prosthesis has been inserted a few centimetres into this mandibular alveolus (306) following oral extraction of a young apically infected tooth. In this particular case, an external sinus tract was present, which necessitated sealing off of the oral cavity following dental extraction and curettage of the sinus tract.

to be separately trephined for lavage. Following extraction by the oral technique, post-operative complications are relatively rare (ca. 15%) compared to dental repulsion.

#### 14.4. Endodontic treatment

A number of workers have also attempted to treat infected CT by use of endodontics (Butson et al., 1997; Baker, 1999; Schramme et al., 2000). A major advantage of successful endodontic treatment is that the infected tooth is preserved and thus will then continue to erupt normally. This prevents the development of overgrowths (“stepmouth”) of the opposing cheek tooth and “drifting” of the adjacent CT into the site of the extracted tooth. This latter “drifting” will eventually cause focal overgrowths on the caudal and rostral aspects of the opposing CT row.

Endodontic treatment of CT is performed through the apex of the tooth, i.e., via surgical approaches through the mandibular or maxillary bones. A consequence of the latter is the need for general anaesthesia and surgical exposure of the dental apex. Many workers have had poor success with CT endodontics, especially in cases with advanced caries, alveolar osteomyelitis or extensive periodontal disease and pulpar exposure. Some cases require two or three courses of treatment, sometimes taking over two hours per treatment under general anaesthesia.

Such repeated and prolonged surgery under general anaesthesia has high economic and safety considerations for the individual horse. It is believed that in the younger horse the presence of a very large common pulp cavity, which is connected to all of the individual pulp horns, is one reason for the failure of this technique in this age group (Kirkland et al., 1996). Consequently, some authors advocate that endodontic treatment should be reserved for more mature teeth (e.g., teeth that have been erupted for at least three to four years) (Kirkland et al., 1996) – but delays in this treatment would also predispose to pulpar exposure and further caries. Specialised training and specialised equipment (including long drills and reamers) are required for endodontic therapy of the long equine pulp canals. Additionally, there is still debate on what is the most suitable filling material (e.g., amalgam or glass ionomer) for equine teeth. Until some larger studies have more fully evaluated the long-term efficacy, costs and safety of this technique in horses of different ages, its role in general equine dentistry remains unclear.

## 15. Dental tumours

Dental tumours can include non-calcified epithelial tumours (which are derived from the epithelium that

forms enamel) which are termed ameloblastomas, that may present as expansive soft tissue density lesions that can cause resorption of adjacent teeth and bone. Dental tumours also include a wide variety of calcified tumours from dentinal tissues (odontoma) or cement (cementoma) or combinations of all three dental components (compound odontoma or ameloblastic odontoma) (Head and Dixon, 1999). These cases usually present as slowly growing, hard focal mandibular or maxillary masses that are usually very radiodense. In general, the mandibular or maxillary lesions associated with these tumours are larger than periapical infection swellings and additionally, they do not have sinus tracts (Pirie and Dixon, 1993; Head and Dixon, 1999). The prognosis depends on how well defined they are to allow effective surgical excision.

## References

- Alexander, K., McMillen, R.G., Easley, J., 2001. Incisor extraction in a horse by a longitudinal forage technique. *Equine Veterinary Education* 13, 179–182.
- Archer, D.C., Blake, C.L., Singer, E.R., Boswell, J.C., Cotton, J.C., Edwards, G.B., Proudman, C.J., 2003a. The normal scintigraphic appearance of the equine head. *Equine Veterinary Education* 15, 243–249.
- Archer, D.C., Blake, C.L., Singer, E.R., Boswell, J.C., Cotton, J.C., Edwards, G.B., Proudman, C.J., 2003b. Scintigraphic appearance of selected diseases of the equine head. *Equine Veterinary Education* 15, 305–313.
- Baker, G.J., 1999. Endodontic therapy. In: Baker, G.J., Easley, J. (Eds.), *Equine Dentistry*, first ed. W.B. Saunders, London, pp. 250–258.
- Barakzai, S.Z., Dixon, P.M., 2003. A study of open-mouthed oblique radiographic projections for evaluating lesions of the erupted (clinical) crown. *Equine Veterinary Education* 15, 143–148.
- Barrairon, P., Blin, P.C., Molinier, F., 1980. Contribution à l'étude du mécanisme de formation de fistule des prémolaires chez le jeune cheval. *Bulletin de l'Académie Vétérinaire de France* 53, 47–54.
- Becker, E., 1962. Zahne. In: Dobberstein, J., Pallaske, G., Stunzi, H., Band, V. (Eds.), *Handbuch der speziellen pathologischen anatomie der haustiere*, third ed. Verlag Paul Parey, Berlin, pp. 121–133. 249–260, 263–265.
- Bennett, D., 1992. The evolution of the horse. In: Evans, J.W. (Ed.), *Horse Breeding and Management*. Elsevier, Amsterdam, pp. 1–37.
- BEVA, 1965. British Equine Veterinary Association survey of equine disease, 1962–63. *Veterinary Record* 77, 528–538.
- Boussauw, B., 2003. Indications and techniques for buccotomy. In: *Proceedings of 42nd British Equine Veterinary Association Congress*, Birmingham, pp. 264–265.
- Brigham, E.J., Duncanson, G., 2000a. An equine post-mortem study: 50 cases. *Equine Veterinary Education* 12, 59–62.
- Brigham, E.J., Duncanson, G., 2000b. Case study of 100 horses presented to an equine dental technician in the UK. *Equine Veterinary Education* 12, 63–67.
- Butson, R.J., Robinson, J., Schramme, M.C., May, S.A., 1997. Endodontic therapy for periapical infection in ten equine cheek teeth: preliminary results. In: *Proceedings of the Fifth World Veterinary Dental Congress*, Birmingham, pp. 143–146.
- Capper, S.R., 1992. The effects of feed types on ingestive behaviour in different horse types. B.Sc. Thesis, University of Edinburgh, Edinburgh.
- Carmalt, J.L., 2003. Understanding the equine diastema. *Equine Veterinary Education* 15, 34–35.
- Colyer, J.F., 1906. Cited by Miles, A.E.W., Grigson, C., 1990. *Colyer's Variations and Diseases of the Teeth of Animals* (revised ed.). Cambridge University Press, Cambridge, pp. 563–567.
- Crabill, M.R., Schumacher, J., 1998. Pathophysiology of acquired dental disease of the horse. *Veterinary Clinics of North America – Equine Practice* 14, 291–308.
- Dacre, I.T., 2004. Equine dental pathology. In: Baker, G.J., Easley, J. (Eds.), *Equine Dentistry*, second ed. W.B. Saunders, London, in press.
- Dacre, K.J., Dacre, I.T., Dixon, P.M., 2002. Motorised equine dental equipment. *Equine Veterinary Education* 14, 263–266.
- Dixon, P.M., 1997a. Dental extractions in horses: Indications and preoperative evaluation. *Compendium of Continuing Education for the Practicing Veterinarian* 19, 366–375.
- Dixon, P.M., 1997b. Dental extraction and endodontic techniques in horses. *Compendium of Continuing Education for the Practicing Veterinarian* 19, 628–639.
- Dixon, P.M., 1999. Dental anatomy. In: Baker, G.J., Easley, J. (Eds.), *Equine Dentistry*, first ed. W.B. Saunders, London, pp. 3–28.
- Dixon, P.M., 2002. The gross, histological, and ultrastructural anatomy of equine teeth and their relationship to disease. In: *Proceedings of the 49th Annual Convention of the American Association of Equine Practitioners*, vol. 48, pp. 421–437.
- Dixon, P.M., Tremaine, W.H., Pickles, K., Kuhns, L., Hawe, C., McCann, J., McGorum, B., Railton, D.I., Brammer, S., 1999a. Equine dental disease part 1: a long-term study of 400 cases: disorders of incisor, canine and first premolar teeth. *Equine Veterinary Journal* 31, 369–377.
- Dixon, P.M., Tremaine, W.H., Pickles, K., Kuhns, L., Hawe, C., McCann, J., McGorum, B.C., Railton, D.I., Brammer, S., 1999b. Equine dental disease part 2: a long-term study of 400 cases: disorders of development and eruption and variations in position of the cheek teeth. *Equine Veterinary Journal* 31, 519–528.
- Dixon, P.M., Tremaine, W.H., Pickles, K., Kuhns, L., Hawe, C., McCann, J., McGorum, B.C., Railton, D.I., Brammer, S., 2000a. Equine dental disease. Part 3: a long-term study of 400 cases: disorders of wear, traumatic damage and idiopathic fractures, tumours and miscellaneous disorders of the cheek teeth. *Equine Veterinary Journal* 32, 9–18.
- Dixon, P.M., Tremaine, W.H., Pickles, K., Kuhns, L., Hawe, C., McCann, J., McGorum, B.C., Railton, D.I., Brammer, S., 2000b. Equine dental disease part 4: a long-term study of 400 cases: apical infections of cheek teeth. *Equine Veterinary Journal* 32, 182–194.
- Easley, J., 1996. Equine dental development and anatomy. In: *Proceedings of the 42nd Annual Convention of the American Association of Equine Practitioners*, pp. 1–10.
- Easley, J., 1999a. Dental and oral examination. In: Baker, G.J., Easley, J. (Eds.), *Equine Dentistry*, first ed. W.B. Saunders, London, pp. 107–126.
- Easley, J., 1999b. Basic equine orthodontics. In: Baker, G.J., Easley, J. (Eds.), *Equine Dentistry*, first ed. W.B. Saunders, London, pp. 206–219.
- Easley, J., 1999c. Equine tooth removal (exodontia). In: Baker, G.J., Easley, J. (Eds.), *Equine Dentistry*, first ed. W.B. Saunders, London, pp. 220–249.
- Easley, J., 2002. A new look at dental radiography. In: *Proceedings of the 48th Annual Convention of the American Association of Equine Practitioners*. Proc. Am. Ass. Equine Pract., pp. 412–420.
- Floyd, M.R., 1991. The modified Triadan system: nomenclature for veterinary dentistry. *Journal of Veterinary Dentistry* 8, 18–19.
- Gibbs, C., 1999. Dental Imaging. In: Baker, G.J., Easley, J. (Eds.), *Equine Dentistry*, first ed. W.B. Saunders, London, pp. 139–172.
- Greene, S.K., 2000. Diagnosis and treatment of equine cheek teeth occlusions. In: *Proceedings of the 14th Annual Veterinary Dental Forum*, Albuquerque, pp. 282–284.

- Greet, T.R.C., 1999. Oral and dental trauma. In: Baker, G.J., Easley, J. (Eds.), *Equine Dentistry*, first ed. W.B. Saunders, London, pp. 60–69.
- Hague, B.A., Honnas, C.M., 1998. Traumatic dental disease and soft tissue injuries of the oral cavity. *Veterinary Clinics of North America – Equine Practice* 14, 333–347.
- Head, K.W., Dixon, P.M., 1999. Equine nasal and paranasal tumours. Part 1: review of the literature and tumour classification. *The Veterinary Journal* 157, 261–268.
- Kempson, S.A., Davidson, M., Dacre, I.T., 2003. The effect of three types of rasps on the occlusal surface of equine CT: a scanning electron microscopic study. *Journal of Veterinary Dentistry* 20, 19–27.
- Kilic, S., Dixon, P.M., Kempson, S.A., 1997a. A light microscopic and ultrastructural examination of calcified dental tissues of horses: 2. Ultrastructural enamel findings. *Equine Veterinary Journal* 29, 198–205.
- Kilic, S., Dixon, P.M., Kempson, S.A., 1997b. A light microscopic and ultrastructural examination of calcified dental tissues on horses: 4. Cement and the amelocemental junction. *Equine Veterinary Journal* 29, 213–219.
- Kirkland, K.D., Baker, G.J., Marett, S.M., Eurell, J.A.C., Losonsky, J.M., 1996. Effects of ageing on the endodontic system, reserve crown, and roots of equine mandibular cheek teeth. *American Journal of Veterinary Research* 57, 31–38.
- Kirkland, K.D., Marett, S.M., Inoue, O.J., Baker, G.J., 1994. Survey of equine dental disease and associated oral pathology. In: *Proceedings of the 40th Annual Convention of the American Association of Equine Practitioners*, pp. 119–120.
- Klugh, D.O., Basile, T., Brannan, R., 2001. Infundibular decay in equine maxillary teeth. *Journal of Veterinary Dentistry* 18, 26–27.
- Lane, J.G., 1993. The management of sinus disorders: Part 2. *Equine Veterinary Education* 5, 69–73.
- Lane, J.G., 1997. Equine dental extraction – repulsion vs buccotomy: techniques and results. In: *Proceedings of the 5th World Veterinary Dental Congress, Birmingham*, pp. 135–138.
- Leue, G., 1941. Cited by Becker, E., 1962 *Zahne*. In: Dobberstein, J., Pallaske, G., Stunzi, H., Band, V. (Eds.), *Handbuch der speziellen pathologischen anatomie der haustiere*, third ed. Verlag Paul Parey, Berlin, pp. 131–132.
- Lowder, M.Q., Mueller, P.O.E., 1998. Dental disease in geriatric horses. *Veterinary Clinics of North America: Equine Practice* 14, 365–380.
- Miles, A.E.W., Grigson, C., 1990. *Colyer's Variations and Diseases of the Teeth of Animals* (revised ed.). Cambridge University Press, Cambridge, pp. 118–124 and 486–492.
- Mueller, P.O., Lowder, M.Q., 1998. Dental sepsis. *Veterinary Clinics of North America: Equine Practice* 14, 349–364.
- Muyll, S., 1999. Aging. In: Baker, G.J., Easley, J. (Eds.), *Equine Dentistry*, first ed. W.B. Saunders, London, pp. 35–46.
- O'Connor, J.J., 1930. *Dollars Veterinary Surgery*, second ed. Balliere Tindall and Cox, London, pp. 481–491.
- Pirie, R.S., Dixon, P.M., 1993. Mandibular tumours in the horse: a review of the literature and 7 case reports. *Equine Veterinary Education* 5, 287–294.
- Pritchard, M.A., Hackett, R.P., Erb, H.N., 1992. Long term outcome of tooth repulsion in horses: a retrospective study of 61 cases. *Veterinary Surgery* 2, 145–149.
- Ralston, S.L., Foster, D.L., Divers, T., Hintz, H.F., 2001. Effect of dental correction on feed digestibility in horses. *Equine Veterinary Journal* 33, 390–393.
- Ramzan, P.H., 2002. The need for chemical restraint while performing routine dental procedures using a full mouth speculum: a retrospective study of 581 examinations. *Equine Veterinary Education* 14, 30–32.
- Rucker, B.A., 2002. Utilizing cheek teeth angle of occlusion to determine length of incisor shortening. In: *Proceedings of the 48th Annual Convention of the American Association of Equine Practitioners*, pp. 448–452.
- Rucker, B.A., 2004. Equine cheek teeth angle of occlusion: how to calculate and clinical use for incisor shortening. *Equine Veterinary Education*, in press.
- Schramme, M., Robinson, J., Boswell, J., Butson, R., 2000. Results of endodontic therapy for periapical infection in nineteen equine CT. In: *Proceedings of the 46th Annual Convention of the American Association of Equine Practitioners*, pp. 119–120.
- Scrutchfield, W.L., 1999a. Dental prophylaxis. In: Baker, G.J., Easley, J. (Eds.), *Equine Dentistry*, first ed. W.B. Saunders, London, pp. 185–205.
- Scrutchfield, W.L., 1999b. Equine dental instrumentation. In: Baker, G.J., Easley, J. (Eds.), *Equine Dentistry*, first ed. W.B. Saunders, London, pp. 173–184.
- Scrutchfield, W.L., Schumacher, J., 1993. Examination of the oral cavity and routine dental care. *Veterinary Clinics of North America – Equine Practice* 9, 123–131.
- Simhofer, H., Griss, R., Zetner, K., 2003. Pathological findings in CT in 300 horses employing a standardised endoscopy technique. *Equine Veterinary Journal*, in press.
- Sisson, S., Grossman, J.D., 1971. In: *The Anatomy of Domestic Animals*, fourth ed. W.B. Saunders, Philadelphia, pp. 396–405.
- Taylor, A.C., 2001. An investigation of mandibular width and related dental disorders in the equine oral cavity. M.Sc. Thesis, Coventry University, pp. 1–55.
- Tietje, S., Becker, M., Bockenhoff, G., 1996. Computed tomographic evaluation of head diseases in the horse: 15 cases. *Equine Veterinary Journal* 28, 98–105.
- Traub-Dargatz, J.L., Salman, M.D., Voss, J.L., 1991. Medical problems of adult horses, as ranked by equine practitioners. *Journal of the American Veterinary Medical Association* 198, 1745–1747.
- Tremaine, W.H., 1997. Oral extraction of equine CT: a Victorian technique revisited. In: *Proceedings of the 5th World Veterinary Dental Congress, Birmingham*, pp. 139–142.
- Tremaine, W.H., 2004. Oral extraction of equine cheek teeth. *Equine Veterinary Education*, in press.
- Tremaine, W.H., Dixon, P.M., 2001a. A long-term study of 277 cases of equine sinonasal disease. Part 1: details of horses, historical, clinical and ancillary diagnostic findings. *Equine Veterinary Journal* 33, 274–282.
- Tremaine, W.H., Dixon, P.M., 2001b. A long-term study of 277 cases of equine sinonasal disease. Part 2: treatments and results of treatments. *Equine Veterinary Journal* 33, 283–289.
- Tucker, R.L., Farrell, E., 2001. Computed tomography and magnetic resonance imaging of the equine head. *Veterinary Clinics of North America – Equine Practice* 17, 131–144.
- Wafa, N.S., 1988. A study of dental disease in the horse. Master of Veterinary Medicine, National University of Ireland, University College Dublin, pp. 1–188.
- Weller, R., Livesey, L., Maierl, J., Nuss, K., Bowen, I.M., Cauvin, E.R., Weaver, M., Schumacher, J., May, S.A., 2001. Comparison of radiography and scintigraphy in the diagnosis of dental disorders in the horse. *Equine Veterinary Journal* 33, 49–58.